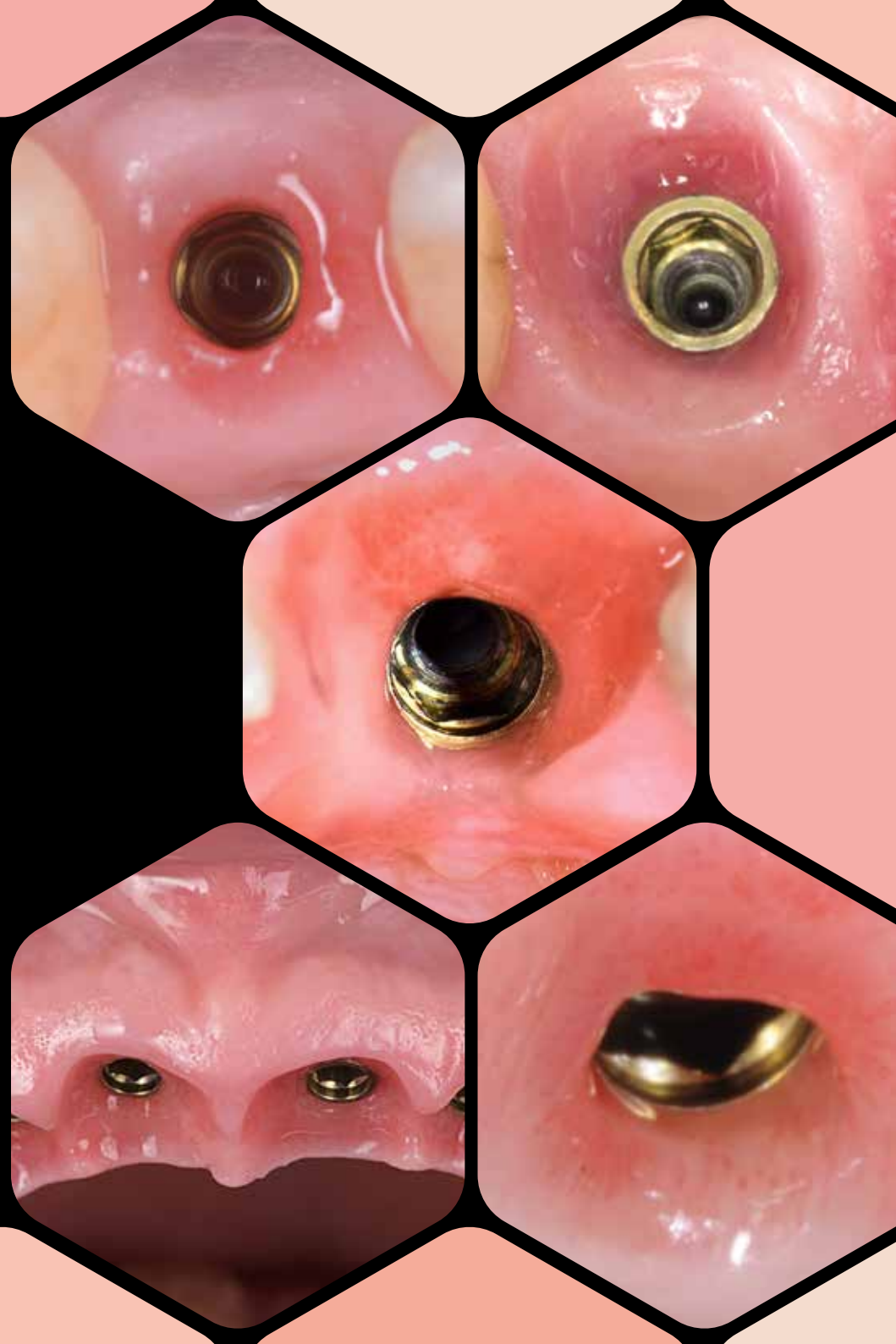


sweden & martina

PRAMA IS PINK FULL

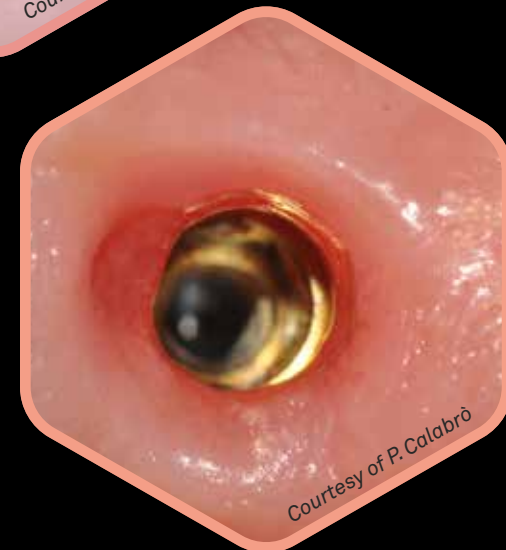
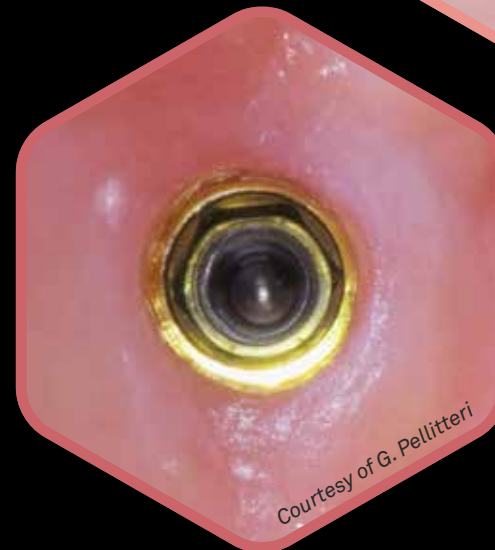
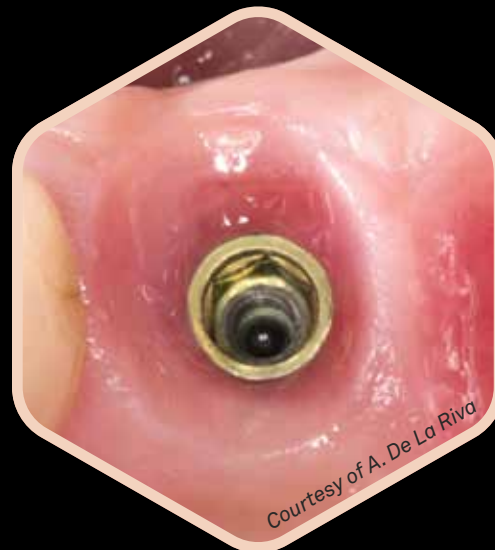
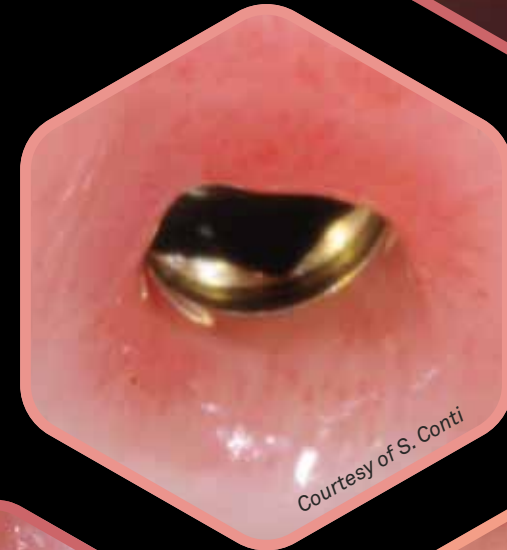
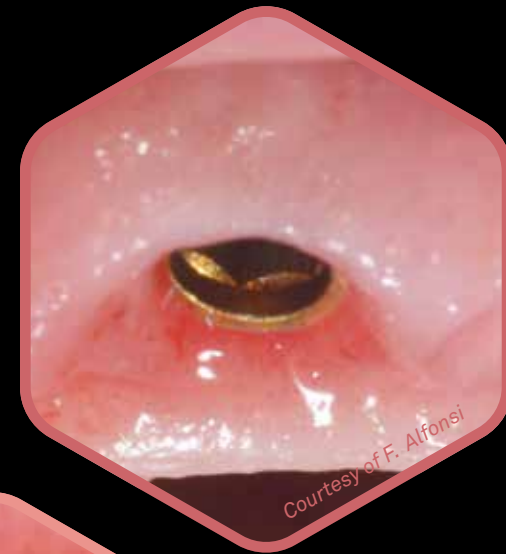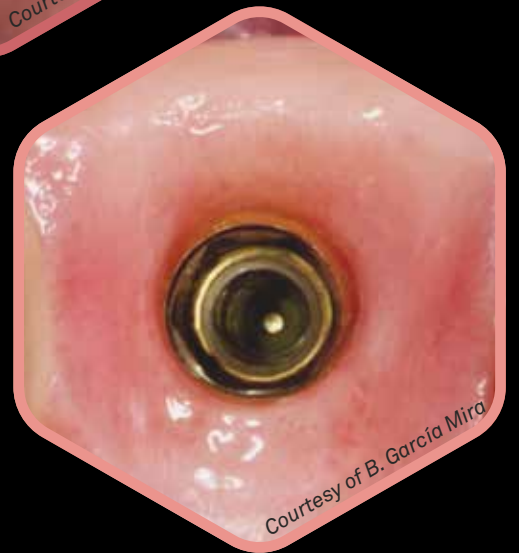
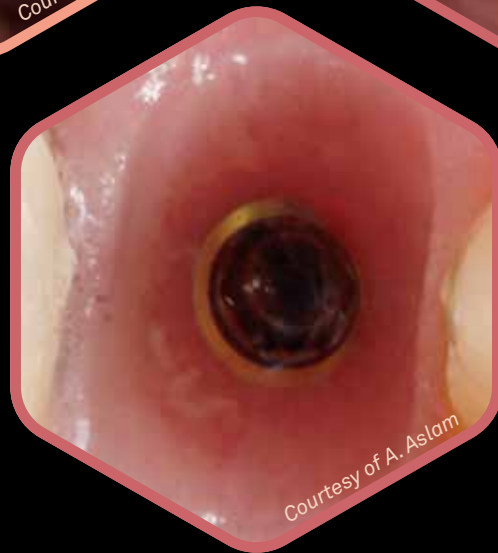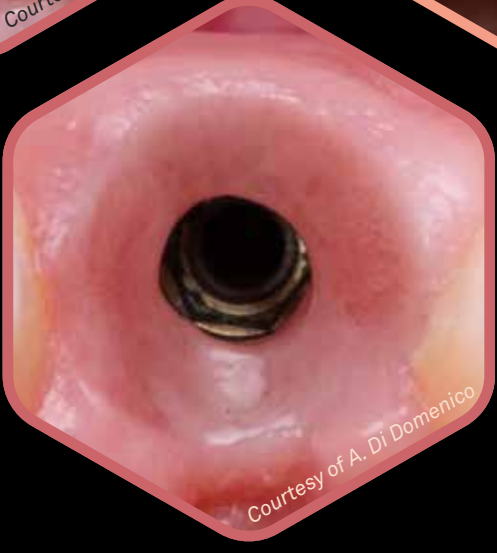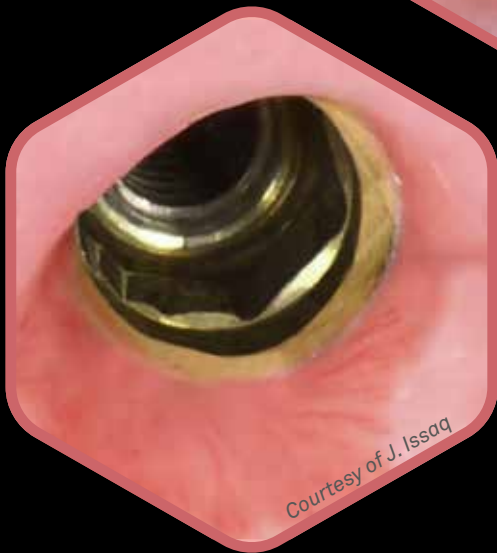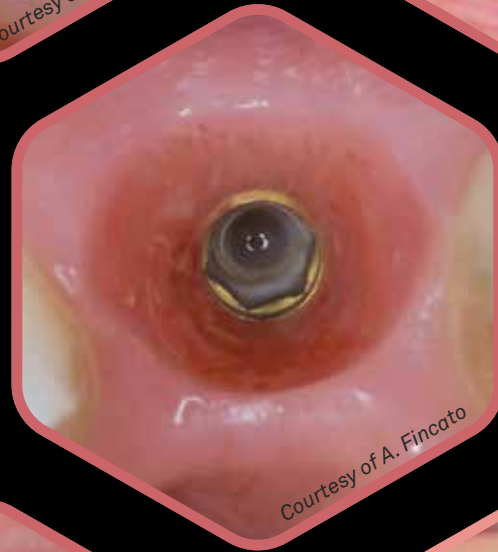
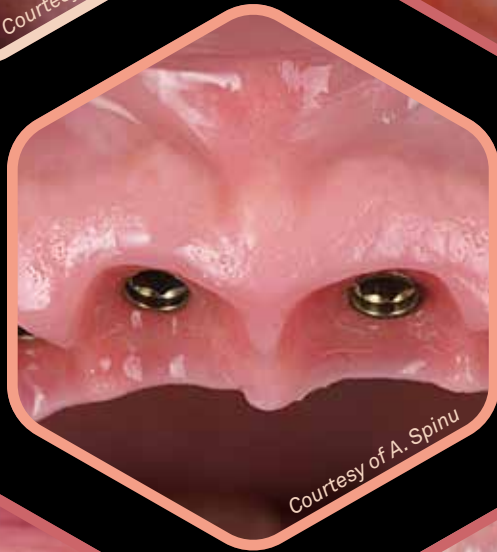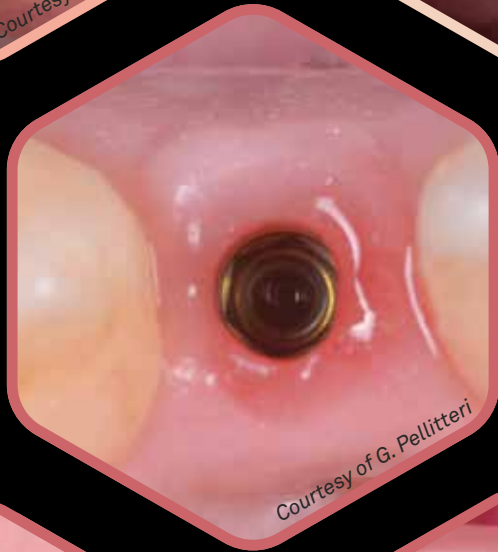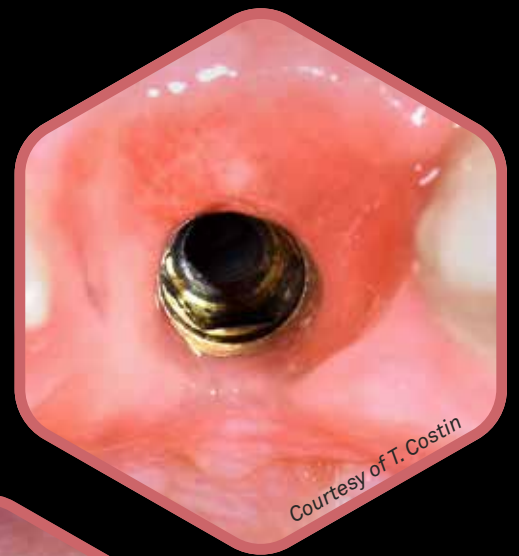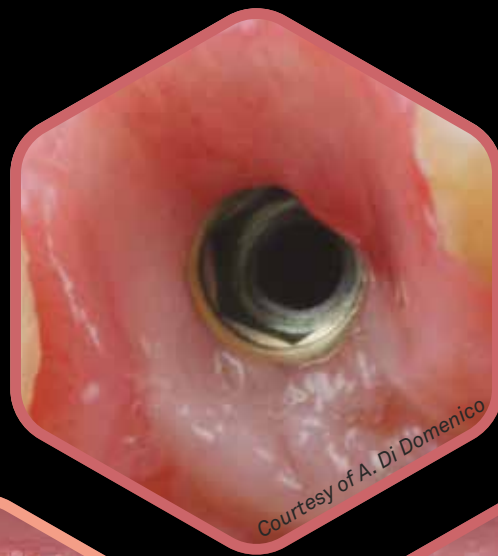
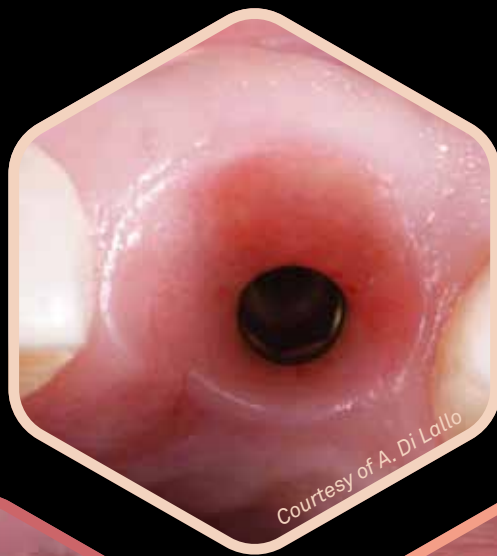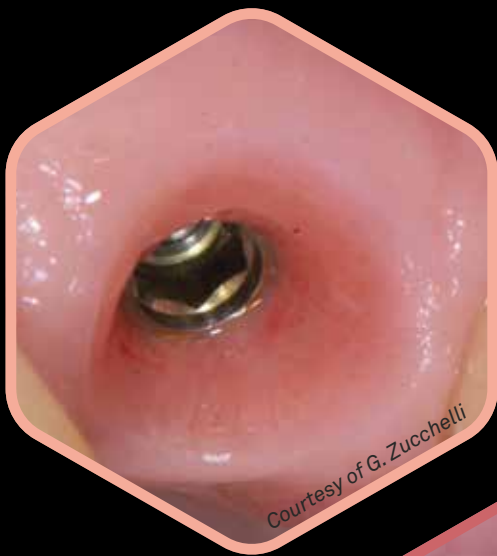What is Pinkfull?

It's the time of soft tissues!

Prama is the first and only intramucosal implant, born from a focus on **soft tissues**, with the aim of making them **healthy, thick, and stable over time**. This approach stems from the awareness of the importance of the supracrestal component of the implant, which requires more space to develop and create a broad connective base that allows for papilla development. This viewpoint is shared not only by many periodontists but also by clinicians from all backgrounds, and it has revolutionized the principles of implantology.

The observation of successful cases now relies on the thickness of the soft tissues, their attachment to the converging portion of the neck or prosthetic component, the presence of neoangiogenesis, the development of papillae, and a prosthetic contour that corresponds to the planned outcome.





Prisma the one and only intramucosal implant


Convergence

Yellow gold neck for better mimetism

Unique in neck shape and micromorphology

More space for soft tissues

The ZirTi surface achieves excellent BIC as demonstrated by clinical research



It facilitates the placement of the prosthetic crown in any portion of the transmucosal pathway

Ideal UTM surface for both soft and hard tissues

Unique connection

Predictable protocols

Biological benefits

Prama necks

What are the characteristics that make Prama intramucosal?

First of all the presence of a neck available in **three different heights** (from 1.80 to 3.80 mm) characterized by a **convergent geometry**: regardless of the endosseous diameter of the implant, the connection diameter always reaches the same dimension. In this way, the space occupied by titanium in transmucosal implants, is left free here for tissue regrowth.

The **Prama Regular Neck** and **Long Neck** implants are more suitable for compensating any discrepancies in post-extraction sites or asymmetric crests, particularly in the esthetic zone.

On the other hand, **Prama Short Neck** implants are more suitable for thin tissues and for the esthetic zone.



Two implant shapes in response to every clinical situation


Prama implants are now available with a new Power endosseous morphology.

The **cylindrical morphology** of Prama implants, with over 18 years of clinical experience, allows for optimal use of the implant design based on the site and its most appropriate application. In particular, the **cylindrical body with a markedly tapered apex** facilitates **insertion into hard, poorly vascularized, and highly cortical bone**. Additionally, it ensures the maximum bone-implant contact surface, favoring a high percentage of BIC (Bone-to-Implant Contact) achievable.



The Prama implant, with its **conical morphology (RF)**, is particularly **suitable for poorly mineralized bone**, where its shape provides maximum stability. The rounded apex of the Prama RF implants makes them ideal for sinus lifts.

The endosseous body of both implant morphologies features a ZirTi surface, which is sandblasted and etched. This surface roughness significantly increases bone-implant contact, promoting osseointegration. The ZirTi surface has proven reliable even in compromised patients, especially when combined with the soft tissue seal that forms around the neck of the Prama implant.




Marchio V, Derchi G, Cinquini C, Miceli M, Gabriele M, Alfonsi F, Barone A,
Tissue level implants in healthy versus medically compromised patients: a cohort comparative study,
Minerva Stomatologica 2020 mese;69(0):000–000, Doi: 10.23736/S0026-4970.20.04359-9

Convergence and UTM

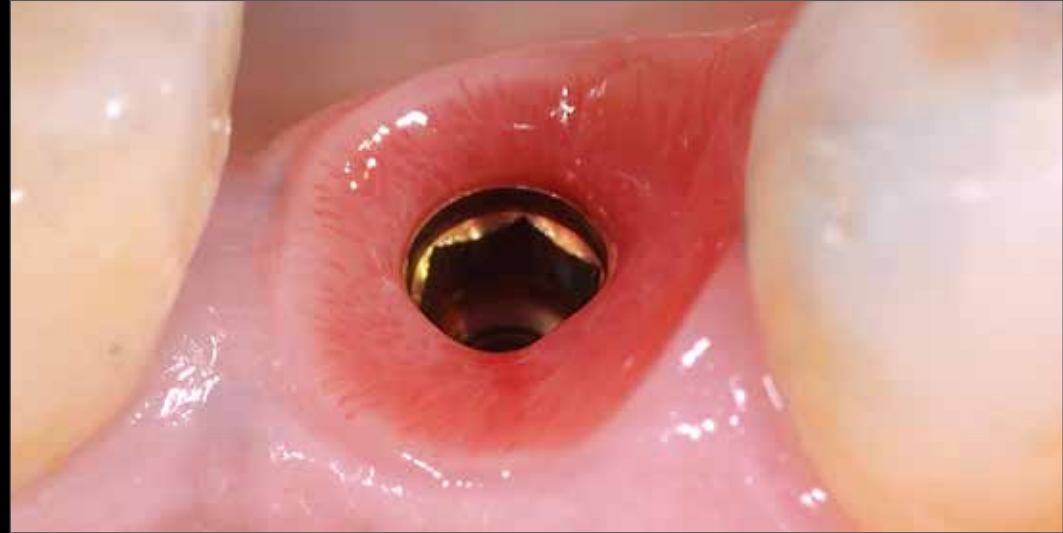
More space for soft tissues

The **convergent morphology of the Prama neck** allows for the preservation of soft tissue volume that would otherwise be occupied by the titanium of a traditional transmucosal implant. The convergence of Prama ensures that the volumes around the coronal portion of the implant are filled with clot and important growth factors, which transform into thick and functional soft tissues.

Convergent profile of Prama implant



Divergent profile of the traditional transmucosal implants



Courtesy of dr. Andrea Di Domenico

The thickening of the gingiva surrounding the Prama neck represents an undeniable benefit for patients with thin biotypes. Proper management of positioning and soft tissues in such cases allows for excellent aesthetic results.

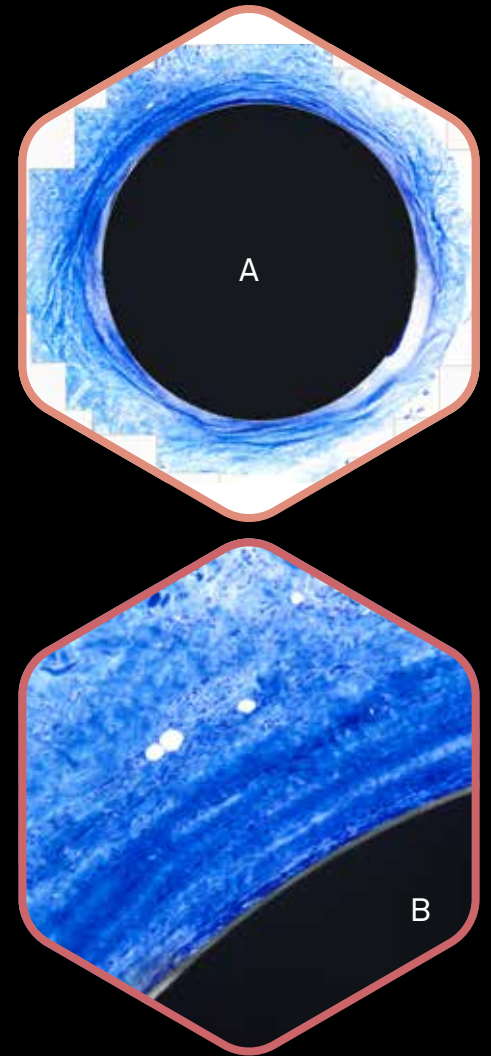

Palombo D., Rahmati M., Vignoletti F., Sanz-Esporrin J., Haugen H. J., Sanz M.,
Hard and soft tissue healing around implants with a modified implant neck configuration: An experimental in vivo preclinical investigation,
Clin Oral Impl Res. 2021;00:1–15.

Mandillo-Alonso V, Cascos Sanchez R, Antonaya-Martin JL, Laguna-Martos M,
Evaluation of peri-implant soft and hard tissues behavior in screw-retained crowns by the biologically oriented preparation technique: Ambispective longitudinal analytical study,
J Clin Exp Dent. 2022 Jan; 14(1): e64–e71, doi: 10.4317/jced.58924

Convergence and UTM

Vertical migration and soft tissue stability

The UTM surface positively influences the activity of fibroblasts and their organization into bundles. The synergy with the converging morphology of the neck enables the formation of a stable tissue ring that adheres well to titanium because the circular fibers trap the perpendicular fibers. The clinical translation of this biological evidence is the keratinized tissue that structures around the Prama neck from the early stages of healing and remains stable over time, molding around the volumes defined by the crown.



Valente N.A., Wu M., Toti P., Derchi G., Barone A,
Concave/convergent versus parallel/divergent implant transmucosal profiles impact on hard and soft peri-implant tissues: a systematic review with meta-analysis,
Int J Prosthodont . Sep/Oct 2020;33(5):553-564. doi: 10.11607/ijp.6726

Agustin-Panadero R, Martinez-Martinez N, L. Fernandez-Estevan, J. Faus-Lopez, F. Sola-Ruiz,
Influence of transmucosal Area Morphology on Peri-implant bone loss in tissue-level implants,
The International Journal of Oral & Maxillofacial Implants, 2019; 34: 947-952. doi: 10.11607/jomi.7329

Histology at 6 months in humans: overall view (A), detail (B), highlighting the course of circular fibers in the thick tissue compartment around the Prama implant neck as seen from above.

Courtesy of dr. Antonio Rocci and prof. Marco Gargari

Convergence and UTM


Greater fiber density

CLINICAL
ORAL IMPLANTS
RESEARCH

Influence of abutment macro- and micro-geometry on orphologic and morphometric features of peri-implant connective tissue


L. Canullo, A. Giuliani, M. Furlani, M. Menini, A. Piattelli, G. Iezzi

A revolutionary human histological study, recently published in Clinical Oral Implants Research, using **synchrotron tomography**, has demonstrated that the **synergy between the convergent profile of the transmucosal component and the UTM surface improves the adhesion and early activation of fibroblasts**, promoting the formation of a biological seal and enhancing the integration of peri-implant soft tissues. **Synchrotron tomography**, along with the significant difference in connective tissue height (vertical thickness) between convergent and divergent groups, also highlighted the significantly positive effect of the **3D micro-ridged UTM surface** (CONV-UTM) compared to the machined convergent surface (CONV-MAC) and even more so compared to the divergent surface (DIV-MAC) in terms of the density of interwoven collagen bundles.



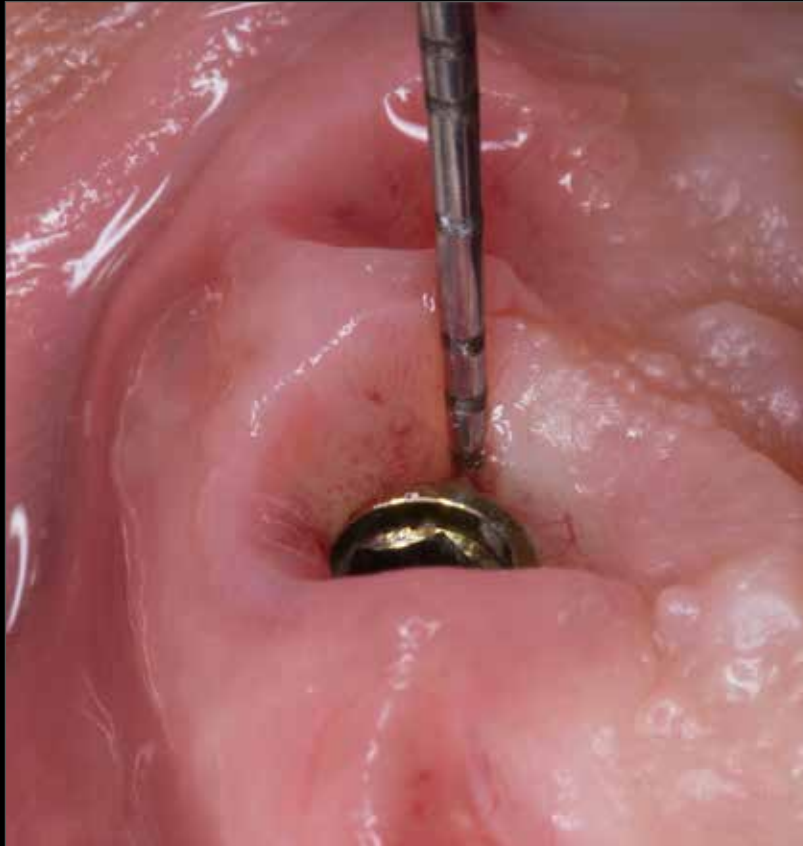The study demonstrated the **positive effect** of the macrogeometry of **convergent abutments** compared to traditional divergent ones in terms of collagen fiber density. The convergent geometry of the implant-prosthetic portion in contact with the soft tissues plays a key role in the quality of peri-implant healing.

Polarized light microscopy of the longitudinal section of the peri-abutment soft tissue around UTM convergent abutment. The light blue (red arrows) indicated the collagen fibers parallel to the vertical profile of the implant-abutment unit, whereas the dark blue color showed the collagen fibers that run perpendicularly or circularly to the implant-abutment unit.

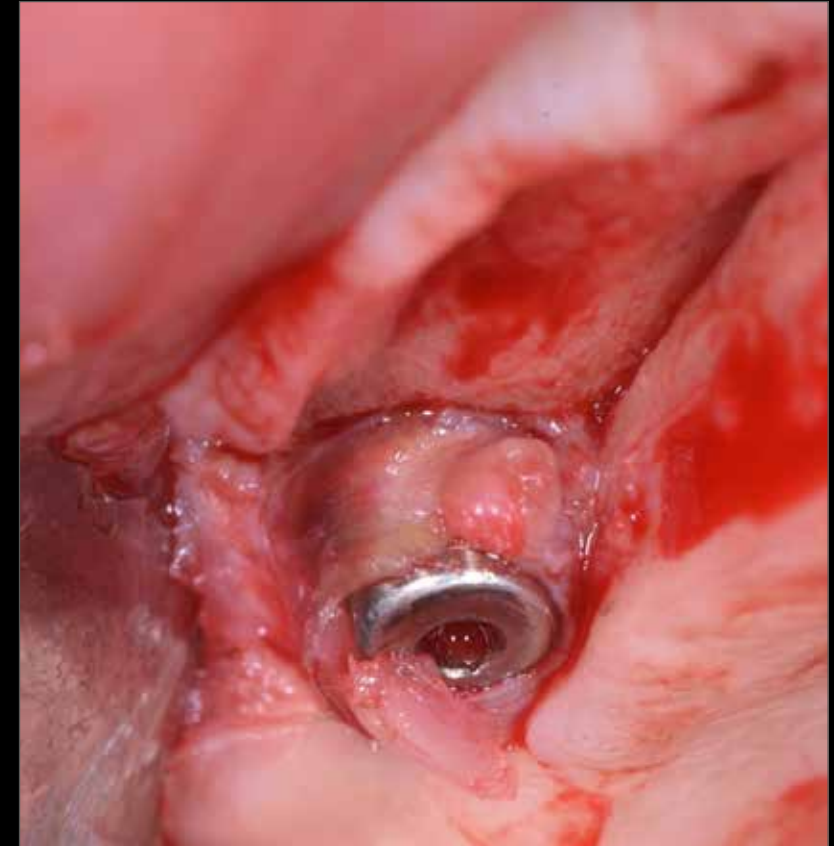


Try to probe!

The benefits provided by the convergence of the neck, combined with those of the UTM surface, allow for **an effective seal at the prosthetic sulcus area**. The outcome of the survey is a **short and horizontal sulcus**, resulting in a highly aesthetic outcome with **stable and functional tissues**.



Courtesy of dr. Lucas Pedrosa



Courtesy of dr. Giuseppe Pellitteri

During the flap elevation for the placement of a second implant adjacent to the existing one, the collagen fibers around the Prama neck are strongly adhered, demonstrating the biological seal that is formed in this area.


Convergence and UTM

Acceleration of the healing process

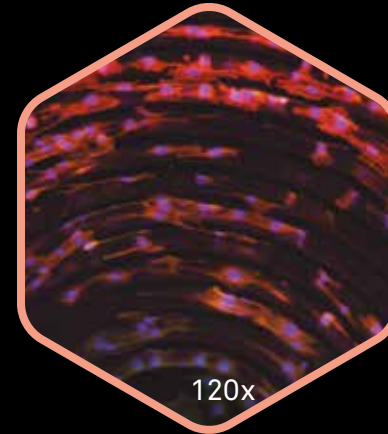
The **implant surfaces** serve as the substrate that interfaces with biological structures after the insertion of the fixture, activating signals that elicit a different cellular proliferation and organization response.

With these premises, Sweden & Martina has developed the **Ultrathin Threaded Microsurface (UTM) treatment**: a microthread with a pitch of 60 microns that runs along the entire neck of the implants. In the Prama implant, it provides guidance for the unidirectional movement of fibroblasts throughout the transmucosal pathway.

The biological benefit is the promotion of rapid cellular activity with low energy consumption. However, the remarkable clinical benefit with Prama is **the acceleration of the healing process and long-term maintenance of stable and healthy tissue**.



Arrangement of murine myofibroblasts on the UTM surface after 72 hours observed with fluorescence microscopy - in vitro experimentation.



The pairs of nuclei that are close but already separated and clearly distinguishable in blue demonstrate that at 72 hours, fibroblasts are in the cytokinesis phase, indicating that they are close to complete duplication. This behavior of the cells in contact with UTM translates clinically into a rapid healing of soft tissues.

*Electron microscope image of UTM surface on the Prama implant neck.
Sweden & Martina's image*

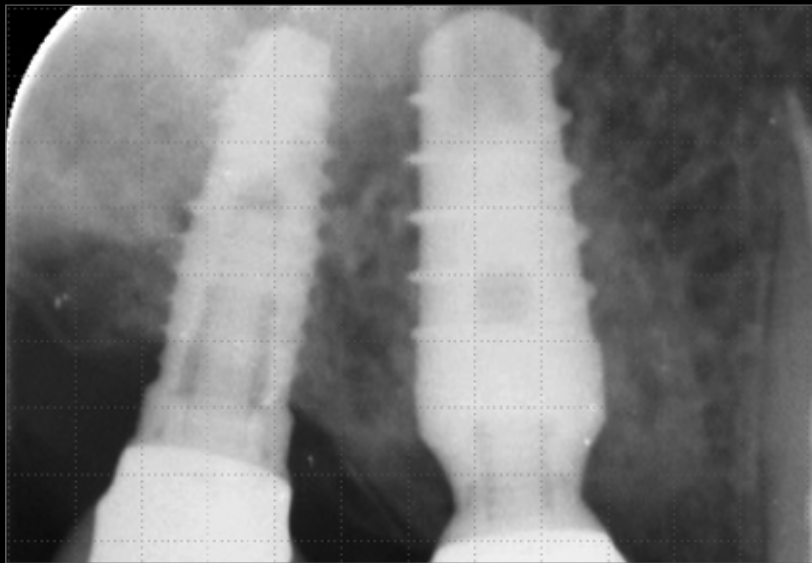
Courtesy of Centro di Odontoiatria dell'Università degli Studi di Parma.

Horizontal and vertical platform switching

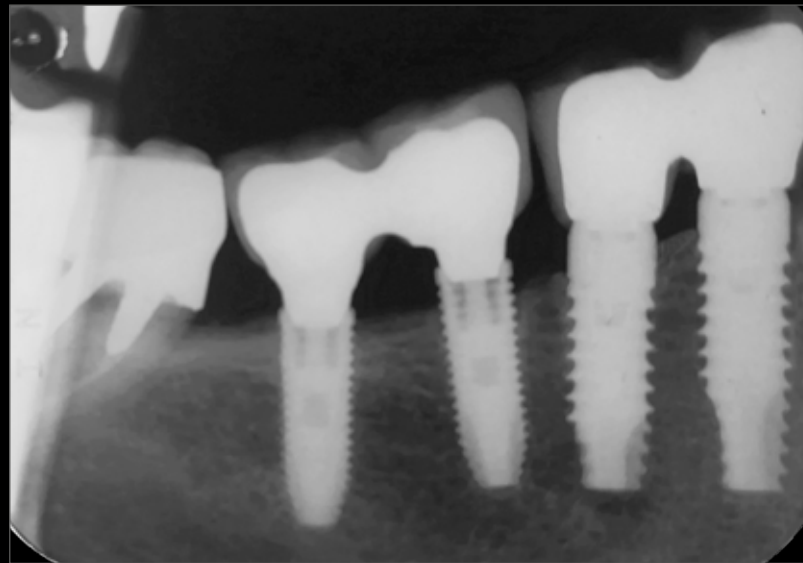
Tissues stability

For many years now, scientific literature has been focused on the concept of **platform switching**, a prosthetic rehabilitation technique that involves using abutments with a smaller diameter than the implant platform.

This technique aims to improve the biomechanical distribution of prosthetic load and, more importantly, to distance the prosthetic connection from the cervical bone, thus moving the critical point of bacterial infiltration away from the bone. It is from this experience that the idea of **maximizing the platform switching with the Prama neck arises, utilizing both its horizontal and vertical components**. Another significant advantage of the Prama neck's geometry is the ability to close the implant-abutment interface within the prosthetic structure, thereby protecting the connection from bacterial infiltration and further reducing the risk of peri-implant infections.



Courtesy of Dentisti Vignato



Courtesy of dr. Marco Gargari

Cabanes Gumbau G, Pascual-Moscardò A, Penarrocha-Oltra D, Garcia-Mira B, Aizcorbe-Vicente J, Penarrocha-Diago M, **Volumetric variation of peri-implant soft tissues in convergent collar implants and crowns using the biologically oriented preparation technique,** *Med Oral Patol Oral Cir Bucal.* 2019 Sep 1;24(5):e643-e651. doi: 10.4317/medoral.22946

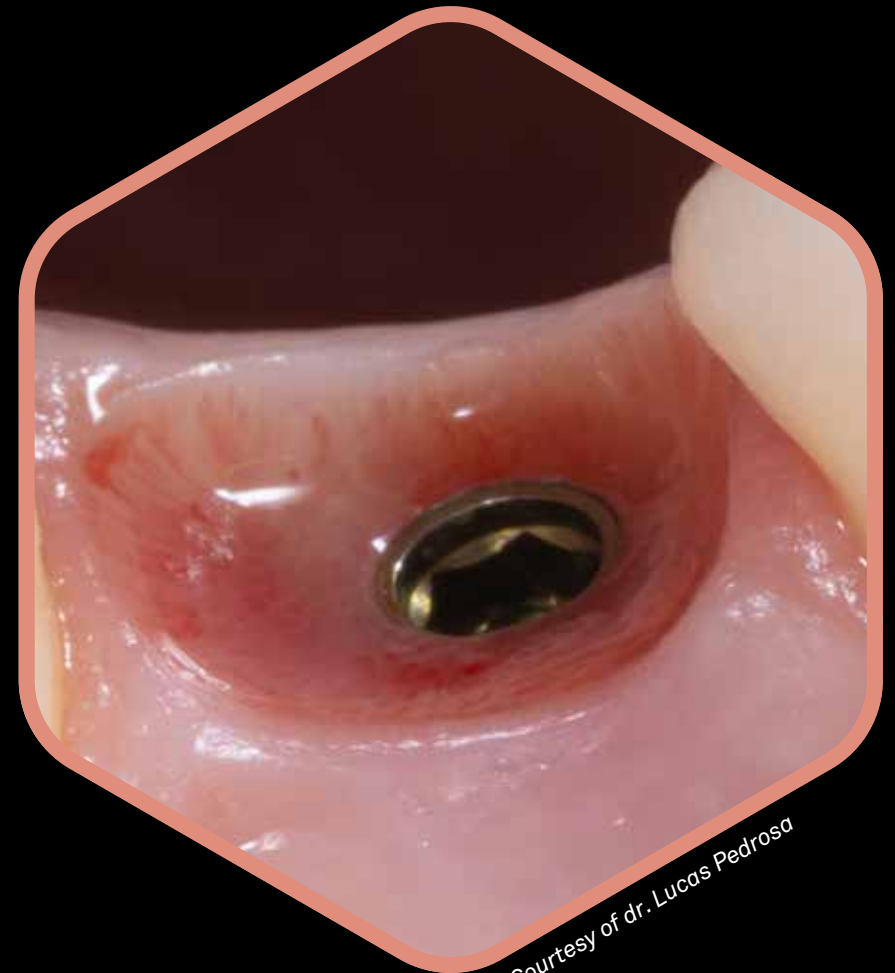Canullo L, Fedele GR, Iannello G, Jepsen S. **Platform switching and marginal bone-level alterations: the results of a randomized-controlled trial.** *Clin. Oral Impl. Res.* 21, 2010; 115–121

Golden neck: great mimetism

The Prama implant **intramucosal neck** undergoes an anodic passivation process that gives it the characteristic golden pale yellow colour, so that it is mimetic under the soft tissues also when the patient's biotype is thin.

The pre-made post also undergoes the same treatment, to create continuity between implant and prosthesis.

The anodized titanium does not increase the accumulation of bacterial plaque not only when compared with non-anodized, but also compared with zirconia.



Courtesy of dr. Lucas Pedrosa

Bressan E., Paniz G., Lops D., Corazza B., Romeo E., Favero G.

Influence of abutment material on the gingival color of implant-supported all-ceramic restorations: a prospective multicenter study

Clin Oral Implants Res . 2011 Jun;22(6):631-7.

Sbricoli L, Paniz G, Abate D, Saldan A, Palu G, Bressan E.

Influence of abutment material and detersion protocol on bacterial adhesion: An in vitro study.

J Oral Science Rehabilitation. 2018 Mar;4(1):32–36.

Canullo L, Menini M, Covani U, Pesce P, **Clinical outcomes of using a prosthetic protocol to rehabilitate tissue-level implants with a convergent collar in the esthetic zone: a 3-year prospective study,**

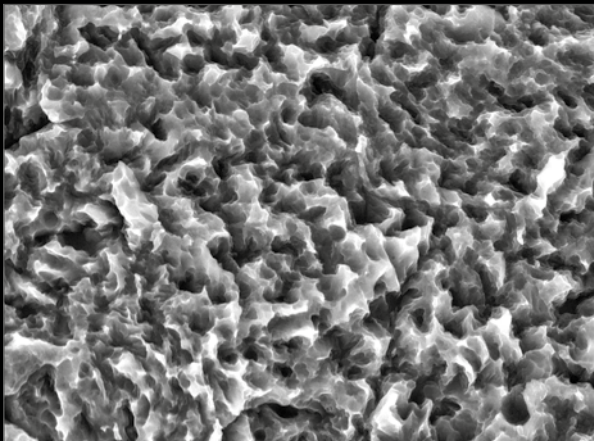
J Prosthet Dent. 2019 Jun 18. pii: S0022-3913(19)30077-0. doi: 10.1016/j.prosdent.2018.12.022

ZirTi surface

Documented osseointegration

The **ZirTi surface** is obtained through a process involving sandblasting with zirconium oxide and subsequent acid etching with mineral acids.

This treatment provides a topography to which osteoblasts have demonstrated close adaptation and rapid proliferation. With its roughness of 1.6-1.7 μm , it falls within the parameters defined by the 2nd Consensus Conference of the EAO (European Association for Osseointegration) to achieve an excellent Bone-to-Implant Contact (BIC).



Electron microscope image of ZirTi surface.


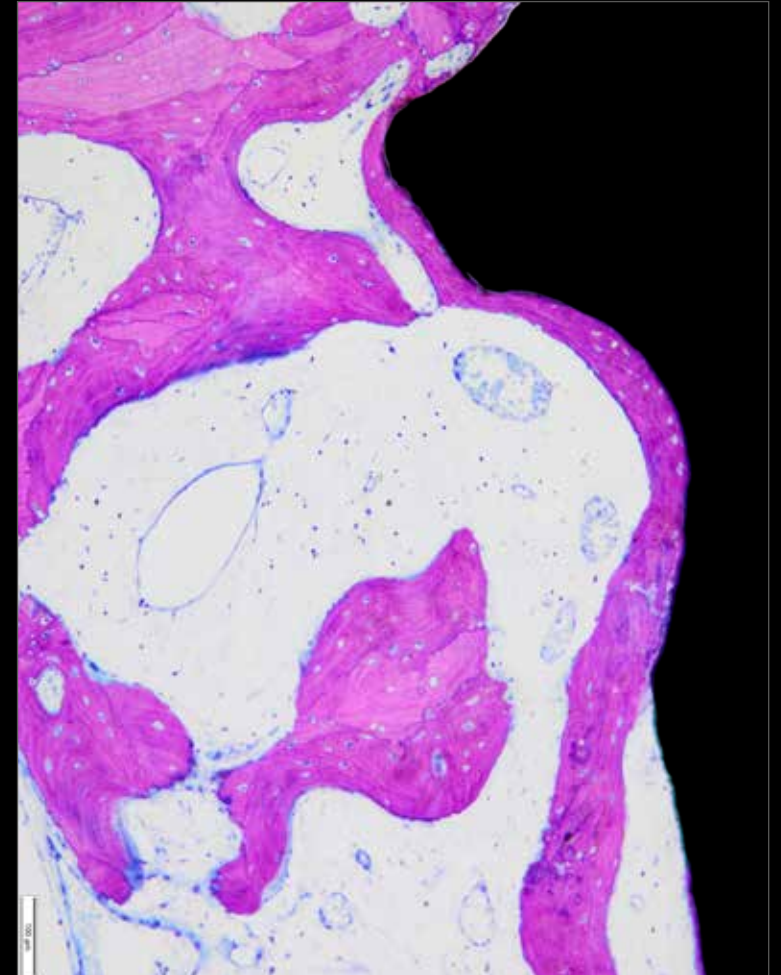


Image of a portion of ZirTi surface obtained using an interferometer: the micro-morphology of the surface and the regularity of the peaks determined by the sand-blasting and acid etching treatment can be noted.



In this histology of poorly mineralized human bone, a layer of newly formed bone is clearly visible progressing on the ZirTi surface.


Courtesy of dr. Antonio Rocci and prof. Marco Gargari

The power of reactive plasma cleaning

Significant biological response

Complete removal of
manufacturing residues
from the implant surface

Larger amount of clean titanium surface in
contact with the bone

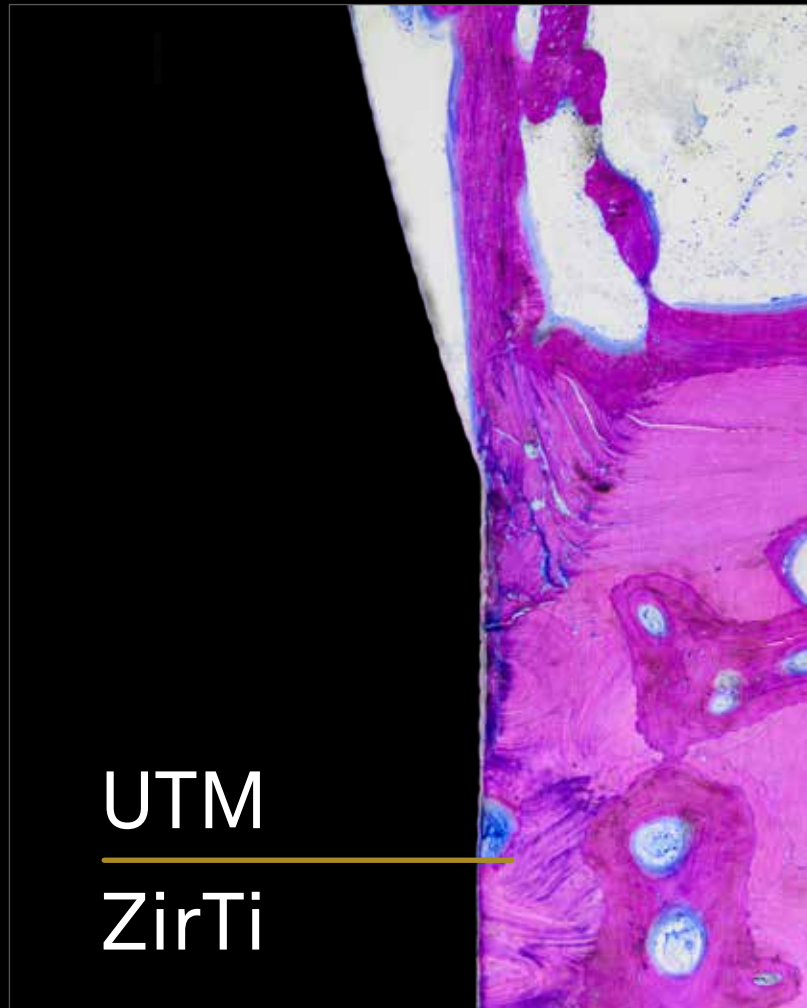


Increased protein
cohesion

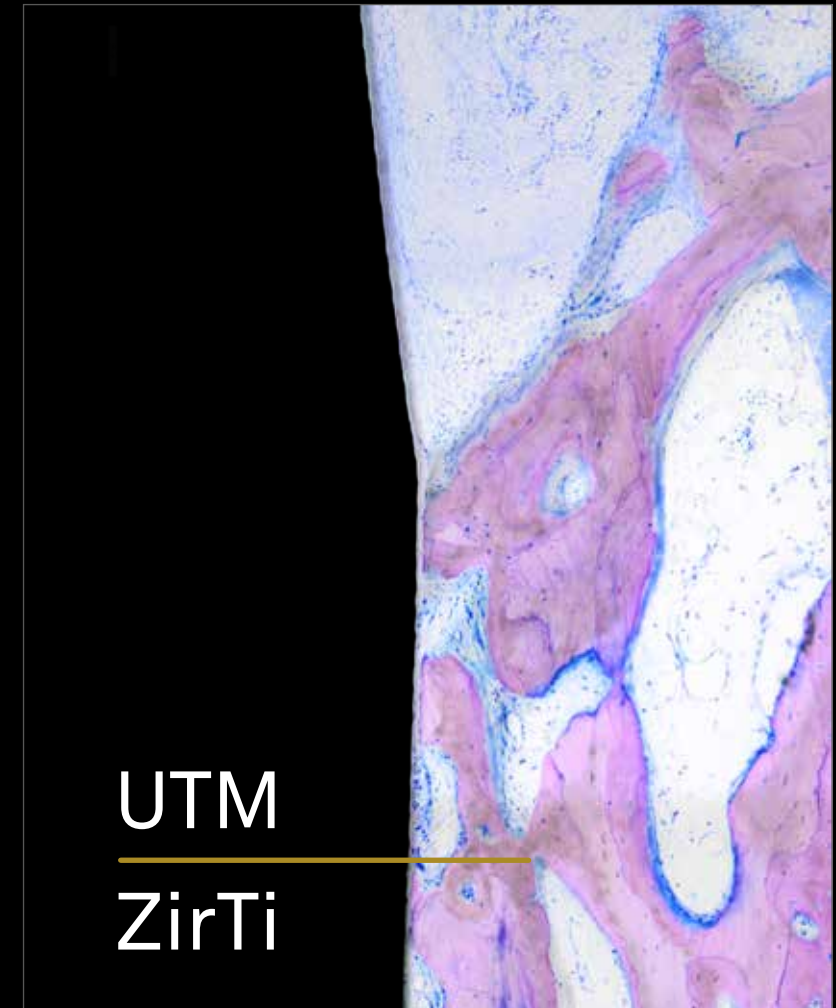
Reduction of reaction time between
cells and titanium

UTM and intramucosal positioning

Not all surfaces are suitable for interaction with both soft and hard tissues. In the case of **UTM treatment**, the microspiral that runs along the entire implant neck has proven to be an excellent substrate for both fibroblasts and, when in contact with bone, for osteoblasts, demonstrating perfect histological and radiographic osteointegration. Histological research conducted first in animals and then in humans shows not only the **presence of mineralized bone tissue at 3 months in contact with the cylindrical portion of the deeper-inserted Prama neck** but also a progressing osteoblastic front moving in a coronal direction.



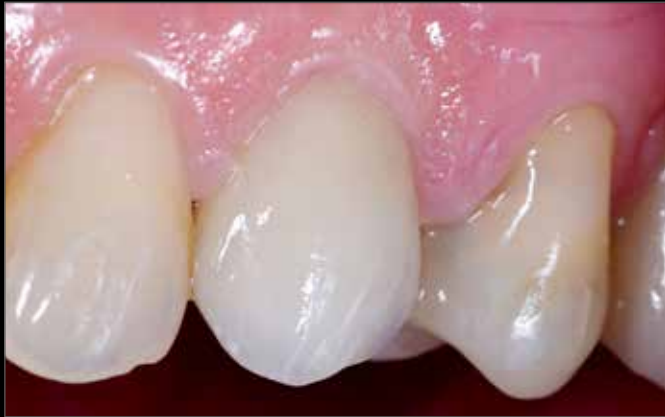Histology of Prama implant in humans at 3 months.



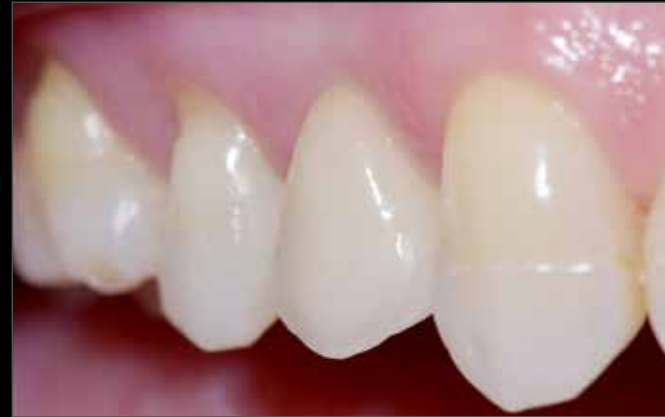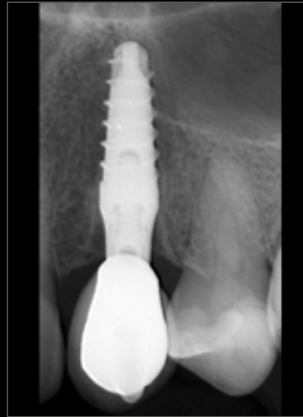Courtesy of dr. Antonio Rocci and prof. Marco Gargari

UTM and intramucosal positioning

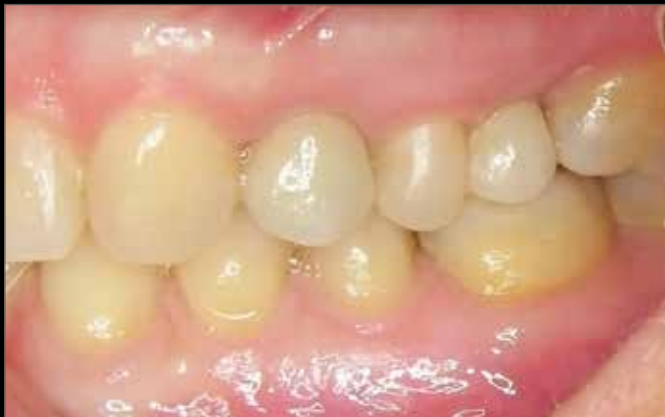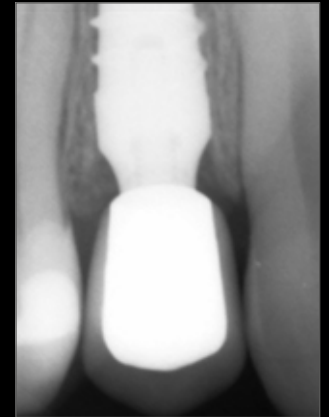
Based on histological evidence of osseointegration of the UTM surface, it is possible to sink the neck of Prama into the bone to achieve the **ideal positioning**, with the prosthetic platform one millimeter below the desired coronal margin. Clinical experience has shown that this approach not only allows for excellent aesthetics but also maintains healthy and stable hard and soft tissues over time.



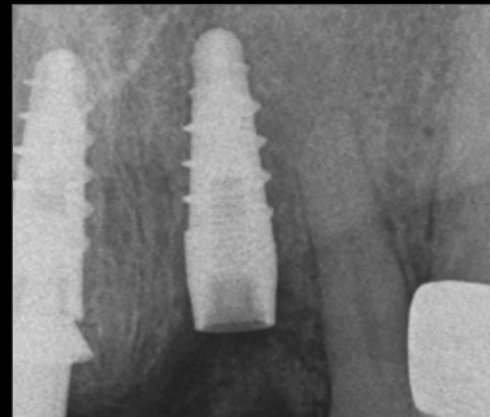
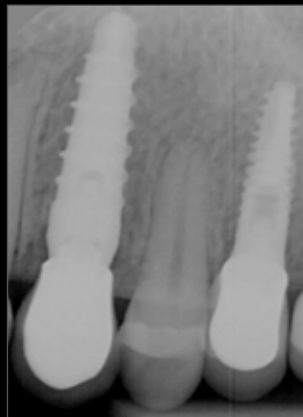Courtesy of Dentisti Vignato



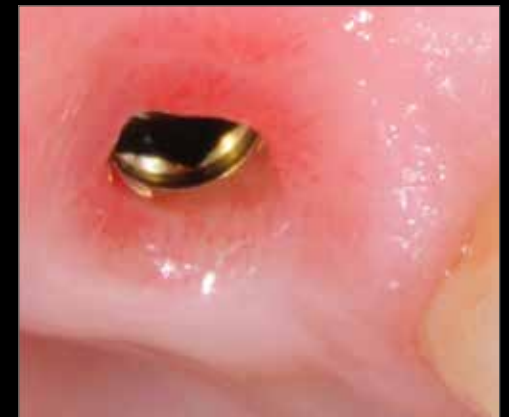Courtesy of Dentisti Vignato



Courtesy of dr. Guillermo Cabanes Gumbau

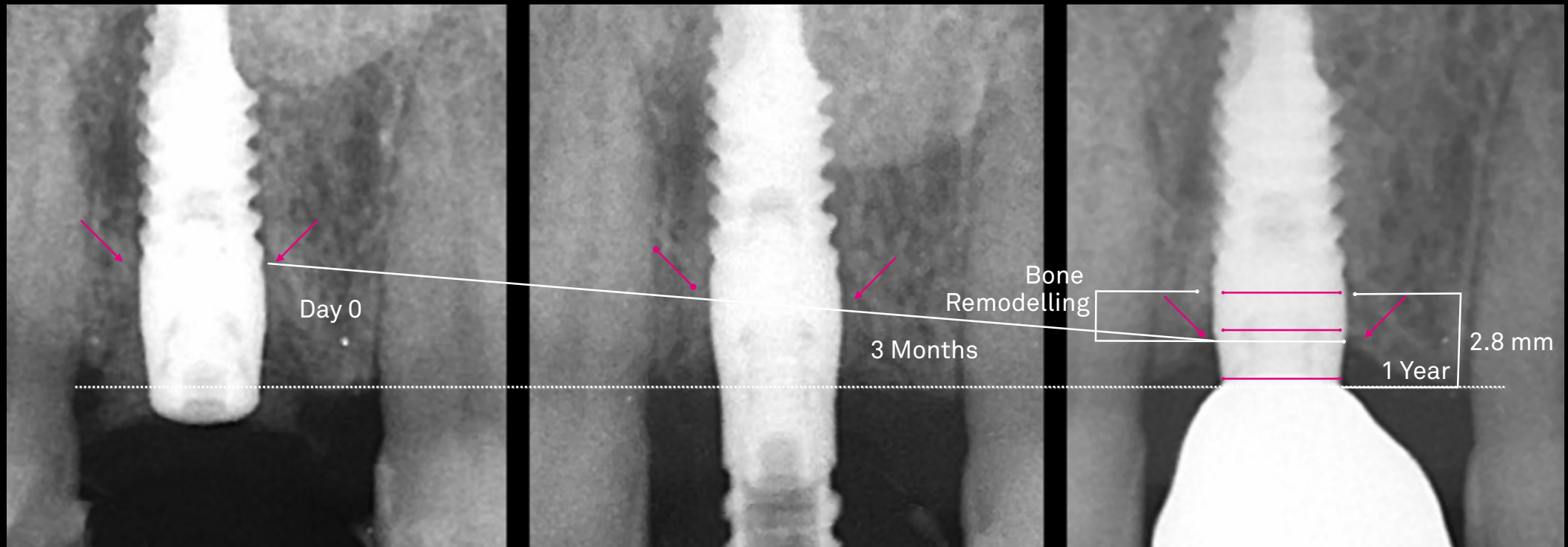


Courtesy of dr. Stefano Conti



Look at the bone!

Bone remodelling and STA neoformation occur immediately apical to the implant platform, ensuring biologic seal and Implant success.



Courtesy of dr. Stefano Conti



Watch the complete clinical case

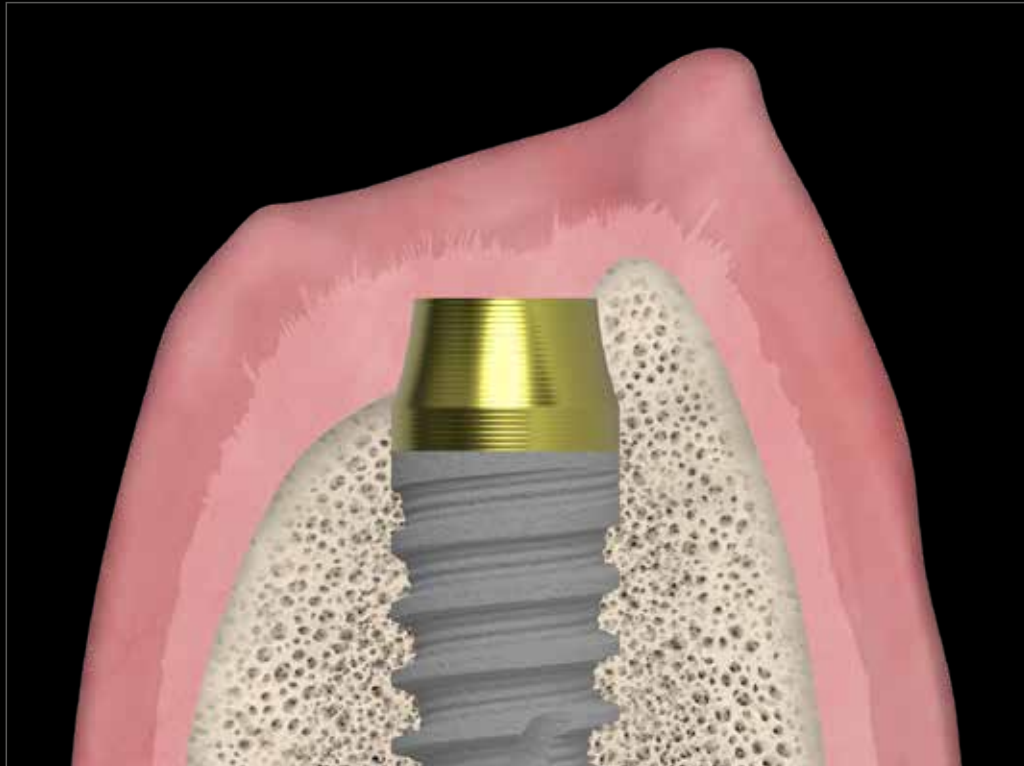
Canullo L., Tallarico M., Pradíes G., Marinotti F., Loi I., Cocchetto R.,
Soft and hard tissue response to an implant with a convergent collar in the esthetic area: preliminary report at 18 months,
Int J Esthet Dent 2017; 12:2-19:

It is surgically versatile in the post-extraction sites

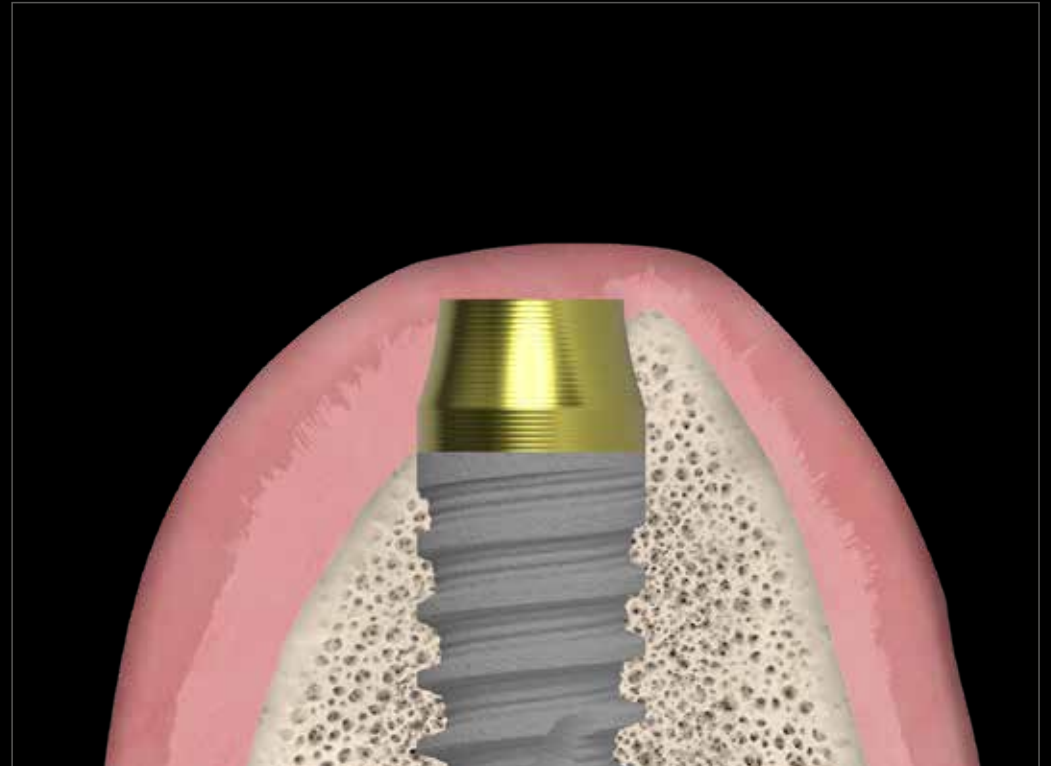
The clinical experience has shown that in immediate **post-extraction procedures** it is possible to preserve the bone peaks of the alveoli because of the convergent neck, which facilitates the maintenance of thick and healthy tissues.

The truncated hyperbolic cone shape allows preserving all the circumferential bone and leaving space for the clot, while the UTM (Ultrathin Threaded Microsurface) treatment of the neck allows an optimal stabilization and organization of the fibres, which accelerates the healing process.

All these aspects contribute to the natural regeneration of the circumferential bone despite initial deficit, showing that the surgical and morphological peculiarities of Prama implants play a primary role reaching the excellent biological and aesthetic results to which Prama users have become accustomed.



Post extraction sockets

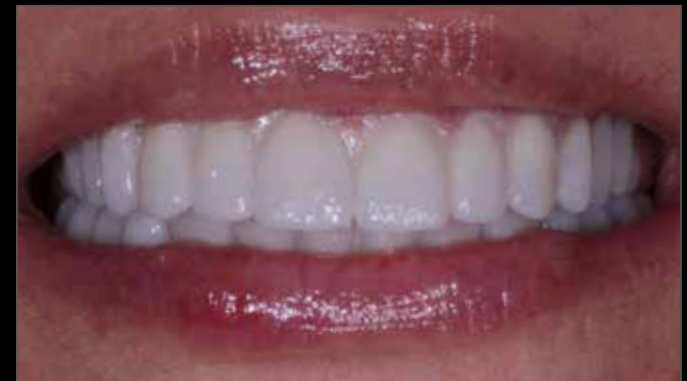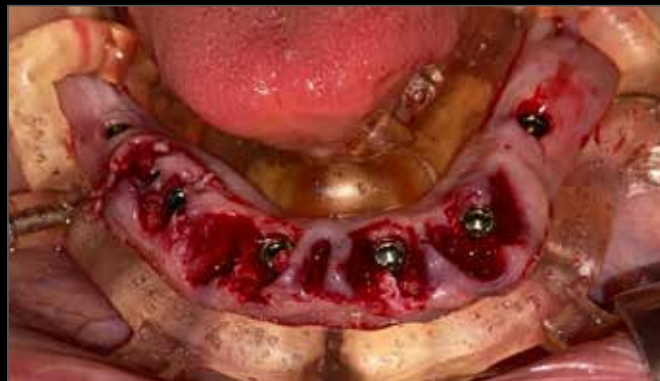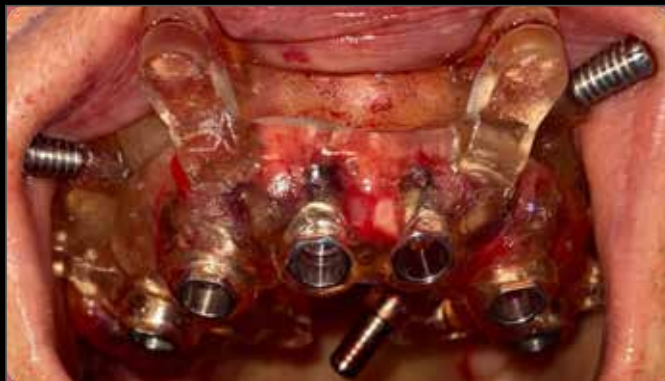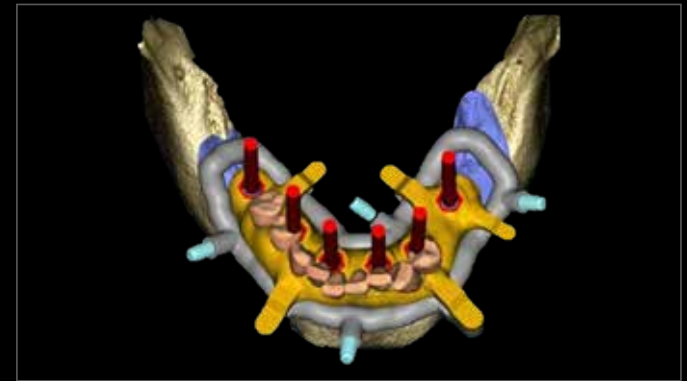


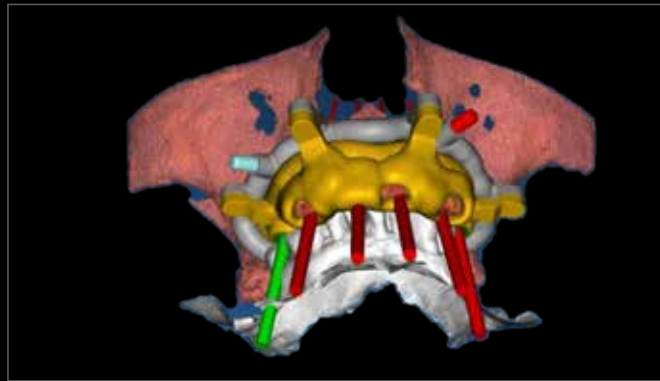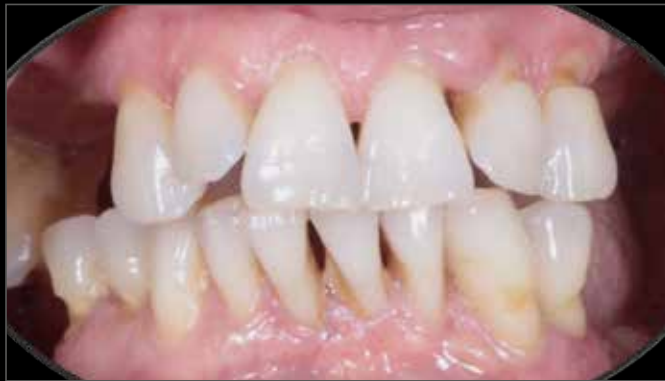Healing

It is surgically versatile

Full digital post-extraction rehabilitation of complete arch with prosthetically driven design

In **immediate post-extraction rehabilitations** with Prama, clinical experience has shown that it is possible to preserve the bone peaks of the residual sockets because the convergent neck does not interfere with the proper positioning of the roughened portion relative to the bone crest and at the same time allows ample space for the blood clot, promoting the maintenance of thick and healthy tissues.



The preservation of bone peaks determines the maintenance of support volumes for the prosthesis.

Courtesy of dr. Davide Di Paola

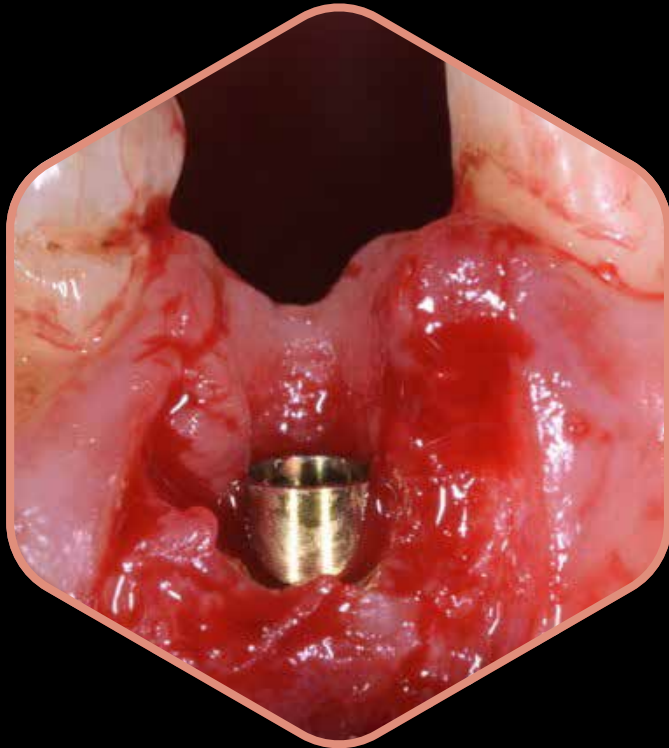
Watch the complete clinical case



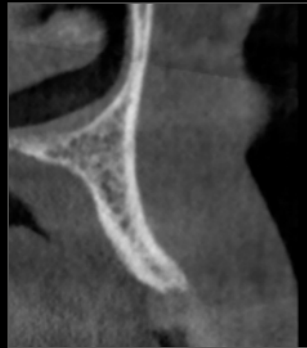It is surgically versatile

Thin ridges

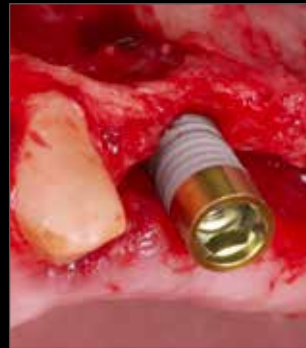When dealing with **particularly thin ridges** or knife-edge ridge configurations (where the most coronal part of the ridge is very thin and then widens significantly after a few millimeters), the use of bone level or transmucosal implants with traditional divergent morphology would require the use of regenerative material to cover the exposed threads, followed by the protection of the site with membranes. Prama allows for addressing these types of clinical challenges with greater predictability and confidence.



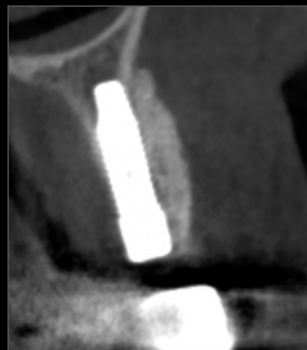
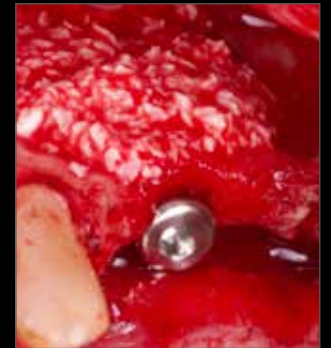
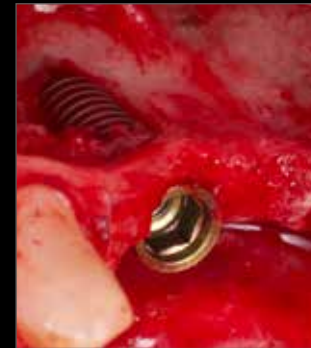Courtesy of dr. Giuseppe Pellitteri



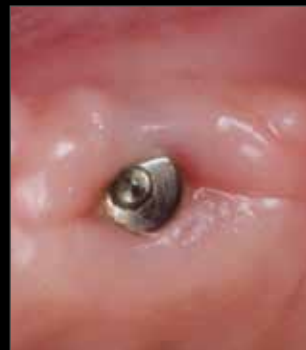Pre-op situation



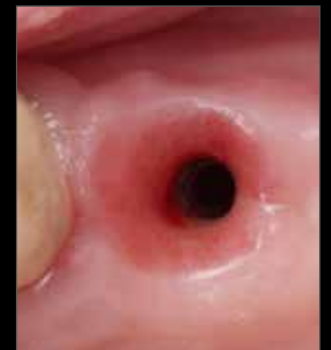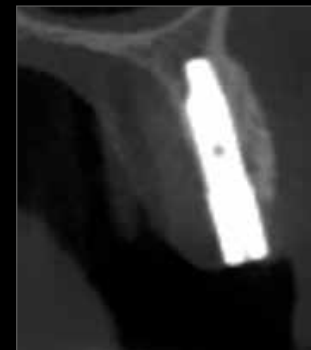Insertion of the Prama Slim implant, which thanks to its geometry make the most of the scarce bone availability. Compensation of the defect with deproteinized bovine bone mineral particles



After surgery CBCT



Clinical and radiographic healing 13 months after surgery



Clinical healing 15 months after surgery


Courtesy of dr. Andrea di Domenico

One connection, all diameters, all lengths

Prama implants are available in **four different diameters**: 3.30 mm, 3.80 mm, 4.25 mm, and 5.00 mm.

They all share a **common connection platform**, equal to 3.40 mm. Prama features the **Collex connection**, which includes an internal prosthetic support collar, providing **excellent prosthetic stability** and overall robustness to the rehabilitation.



The **internal hexagon** connection ensures stability and enhances the **prosthesis' resistance to masticatory loads**.



Complete prosthetic range

Convergent shoulderless solutions without are available, with narrow or convergent profile, in which the crown can be positioned at different levels (L-MD or L-MDT). These solutions promote soft tissue thickening because they leave more space for connective.

When single rehabilitation concerns an last molar element, the recommendation is to use a "Prima IN" prosthetic solution which closes around the implant neck, allowing greater robustness to the rehabilitation, also in light of the important typical chewing loads of that area. The "Prima IN" prosthetic solutions may also represent a valid option in cases where, due to factors related to the patient's immune system response, bone and tissue remodeling was not the desired one.



CONICO prosthetic system: fixed prosthesis without screws or cement; easy to remove: at any time the clinician can remove the prosthesis to perform a follow up and/or the hygiene; the conometric technique allows restorations from single elements to entire arches; biological seal and healthy and stable tissues over time.

P.A.D.r: easy to insert abutments. Maximum freedom and ergonomics of the superstructures. Pink anodization for better mimetism. Their limited size makes them suitable for rehabilitations of partially or totally edentulous arches in reduced horizontal and vertical spaces.

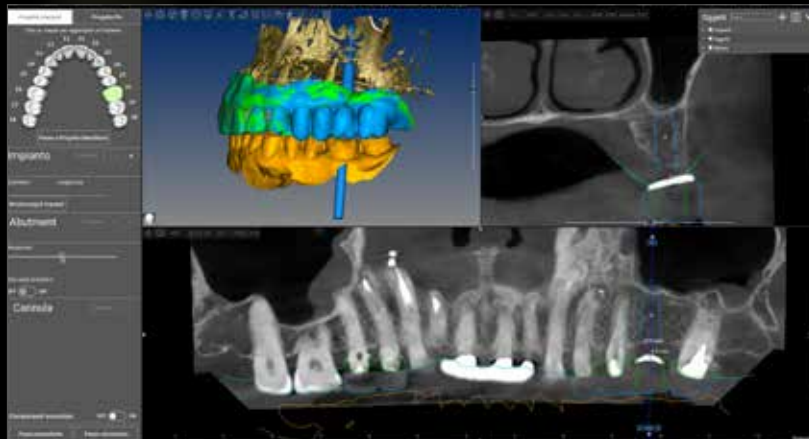
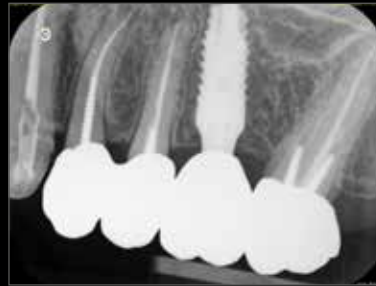Standard or cuttable T-Connects for straight or angled screw hole.

Excellence in prosthetics

The Prama philosophy is to leave more space for soft tissues. Prama implants offer a rich selection of prosthetic components that allow for the rehabilitation of single crowns, bridges, and full arches in all situations, with a digital workflow. Both abutments without a repositioning shoulder, leaving the decision to the clinician on where to position the prosthetic margin, and abutments or bases for adhesive bonding with a predefined support base for crown bonding, are available. There are options for both cemented and screw-retained prostheses, for both digital and analog workflows. In the case of screw-retained prostheses, it is possible to opt for the presence of an angled screw hole.



*L-MD for
straight screw hole*



Courtesy of dr. Massimiliano Visca

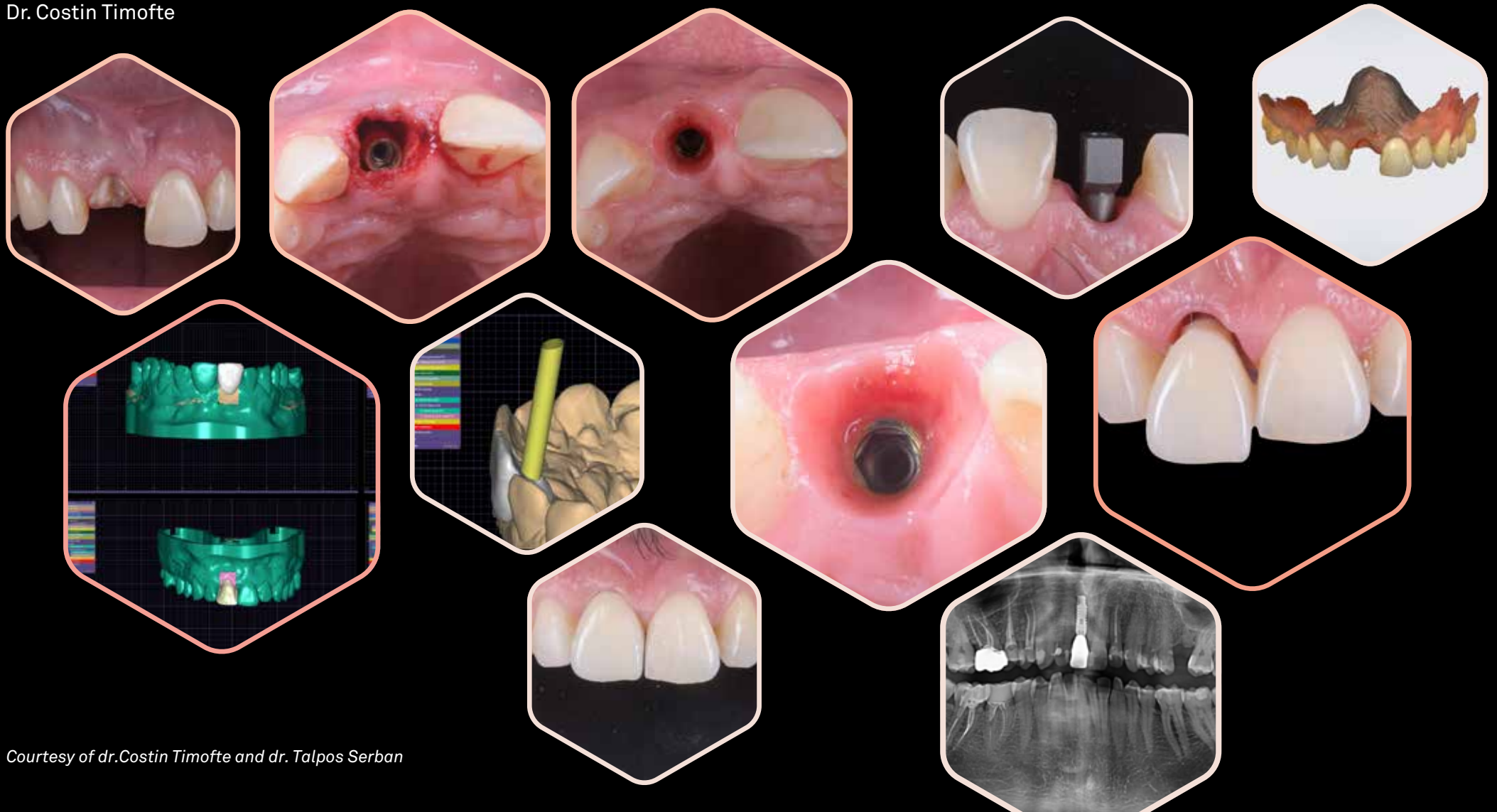


L-MDT for angled screw hole

The single incisor challenge...

"With Prama you can easily achieve the best esthetic results even without a ctg. In this case we recovered the teeth because of a fracture, we immediately placed a Prama implant and did a provisional because the torque was 40 Ncm². After the healing, digital impression was performed and we did using a lmdt abutment the final ZR ceramic restoration according with biologic principles. The integration was excellent and the follow up is amazing... after 2 years the rx show 0 bone loss".

Dr. Costin Timofte



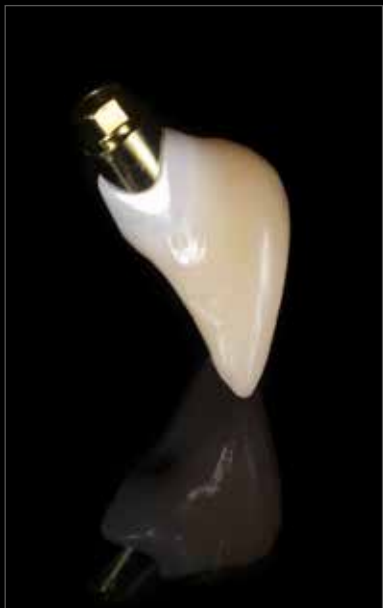Courtesy of dr.Costin Timofte and dr. Talpos Serban

Excellence in prosthetics

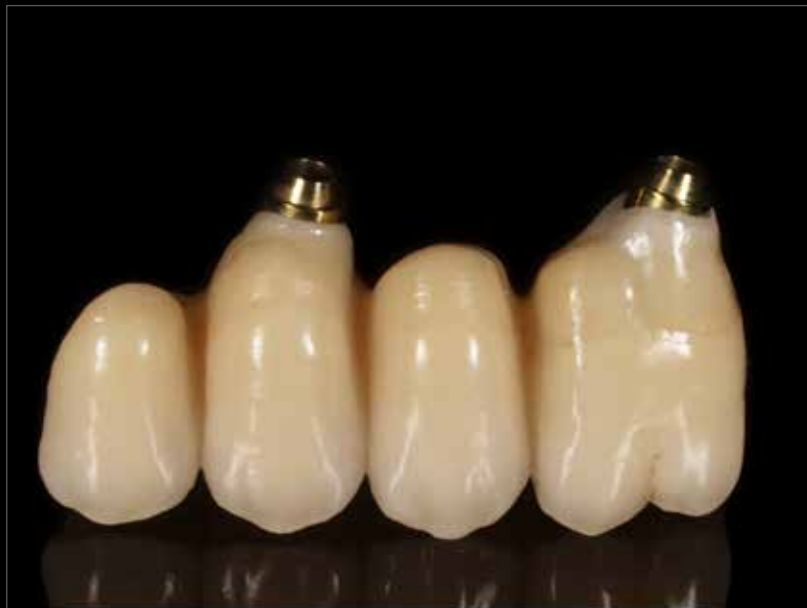Custom-made prosthesis on L-MDT abutment and dynamic screw

The custom-made prosthesis offers personalized solutions using advanced technologies such as intraoral scanning and CAD/CAM modeling, ensuring perfect adaptability and functionality.

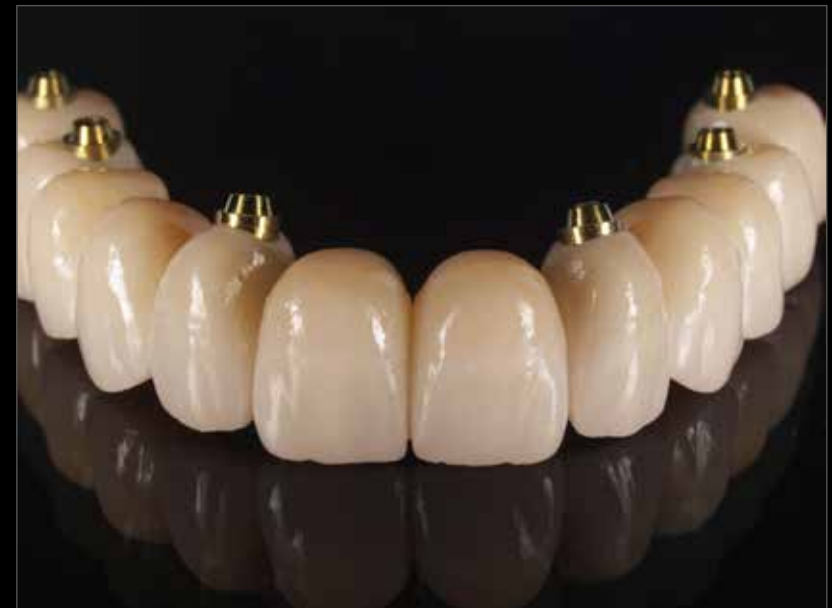Custom-made prosthetics in dentistry represent the present and future of oral rehabilitation, providing tailor-made solutions for every patient's need and excellent aesthetic results.



Single crown



Bridge



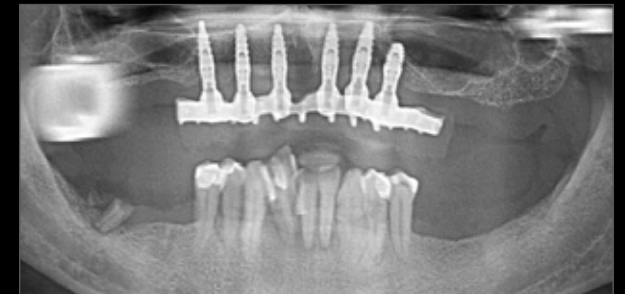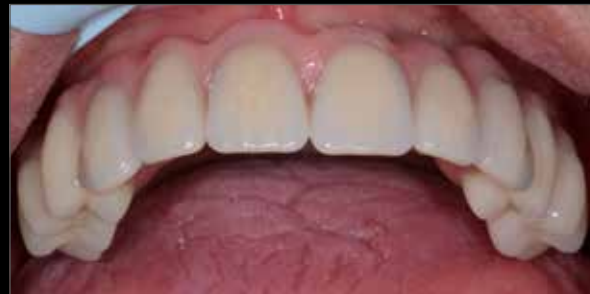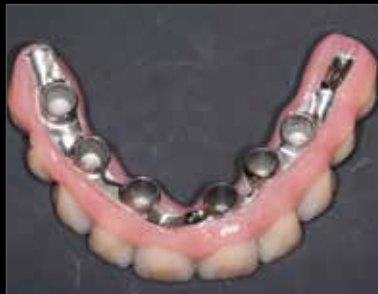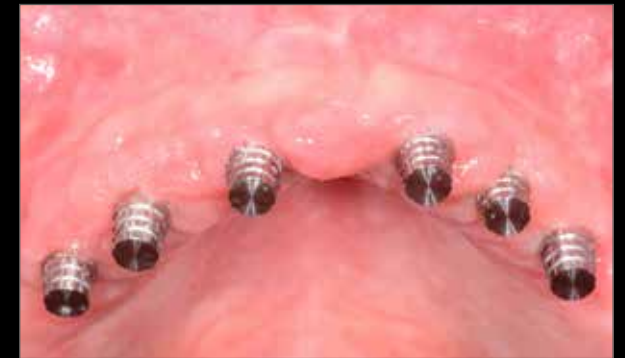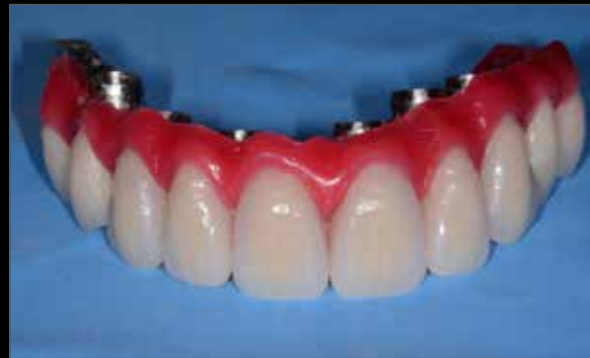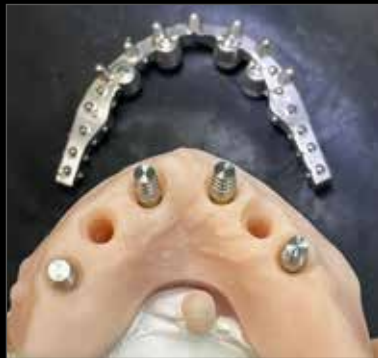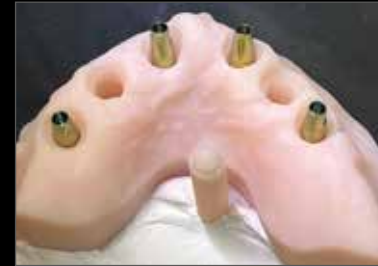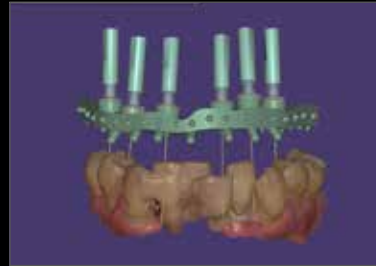
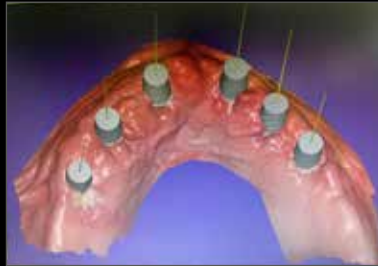Full arch

Courtesy of dr. Costantino Vignato and dt. Riccardo Finotello

Conico

Full digital approach

Conico system allows to obtain a fixed restoration on implant without the use of cement or fixation screws between the post and the prosthesis, and at the same time easily removable by the clinician. The conometric prosthesis is to be considered a fixed prosthesis, like screw retained and cemented solutions and combines the advantages of both: revision and absence of cement of the screw-retained prosthesis and aesthetics and absence of holes in the occlusal area of the cemented prosthesis. Moreover, the ease of removal allows a correct maintenance of the health of the peri-implant tissues, with a considerable saving of time and costs for both the patient and the technician.



Courtesy of dr. Giuseppe Sepe and dt. Giovanni Macone

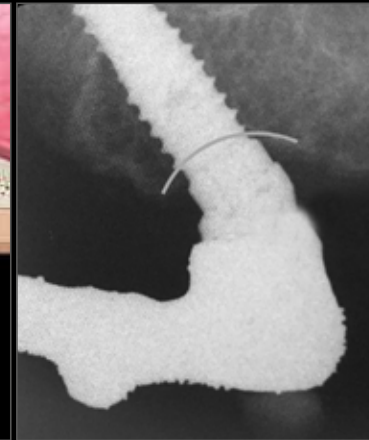
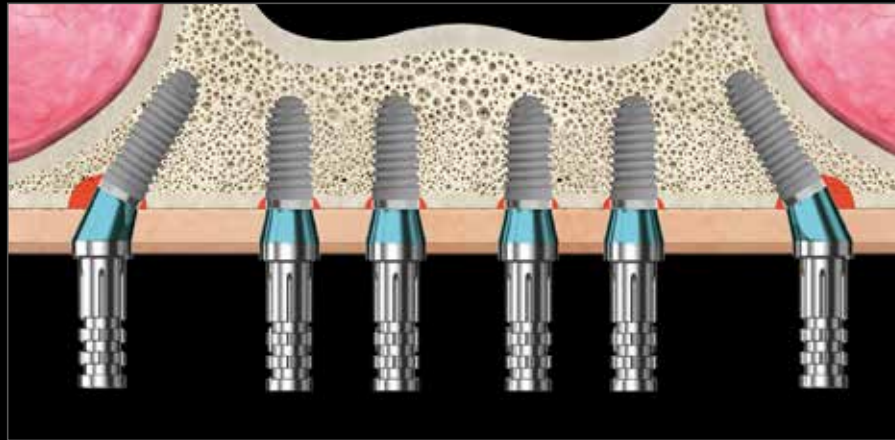
All on Prama

P.A.D.r Disparallel Screw Retained Prosthesis

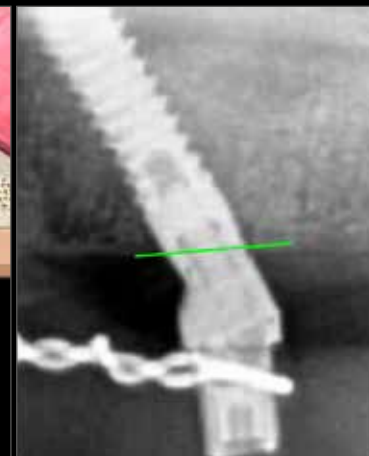
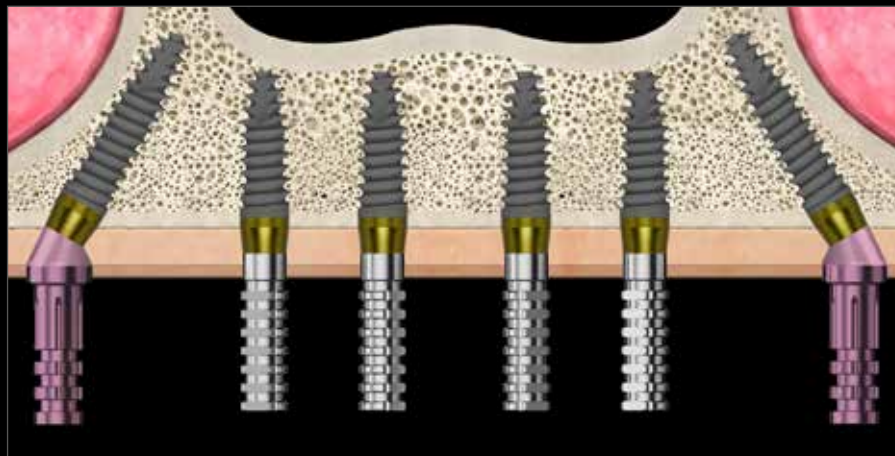
When a completely edentulous arch is restored with traditional submerged implants it is necessary to use intermediate abutments both on the angled distal implants and on the straight mesial implants. Moreover the distal margin of the angled implants has to be submerged, with a resulting crestal bone loss and with difficulties due to the very deep position of the implant connection.

However, by using intramucosal Prama implants it is possible to avoid the use of intermediate abutments in the frontal sector, positioning only the preangled ones on the distal implants (**abutment P:A.D.r the pink ones in the image**).

Moreover the conformation of the convergent neck allows to position the distal margin of the tilted implants at crestal level and the mesial margin at intramucosal level, avoiding the need to use a bone profiler.



An example of a solution for a full arch with distally inclined implants of the bone level type.



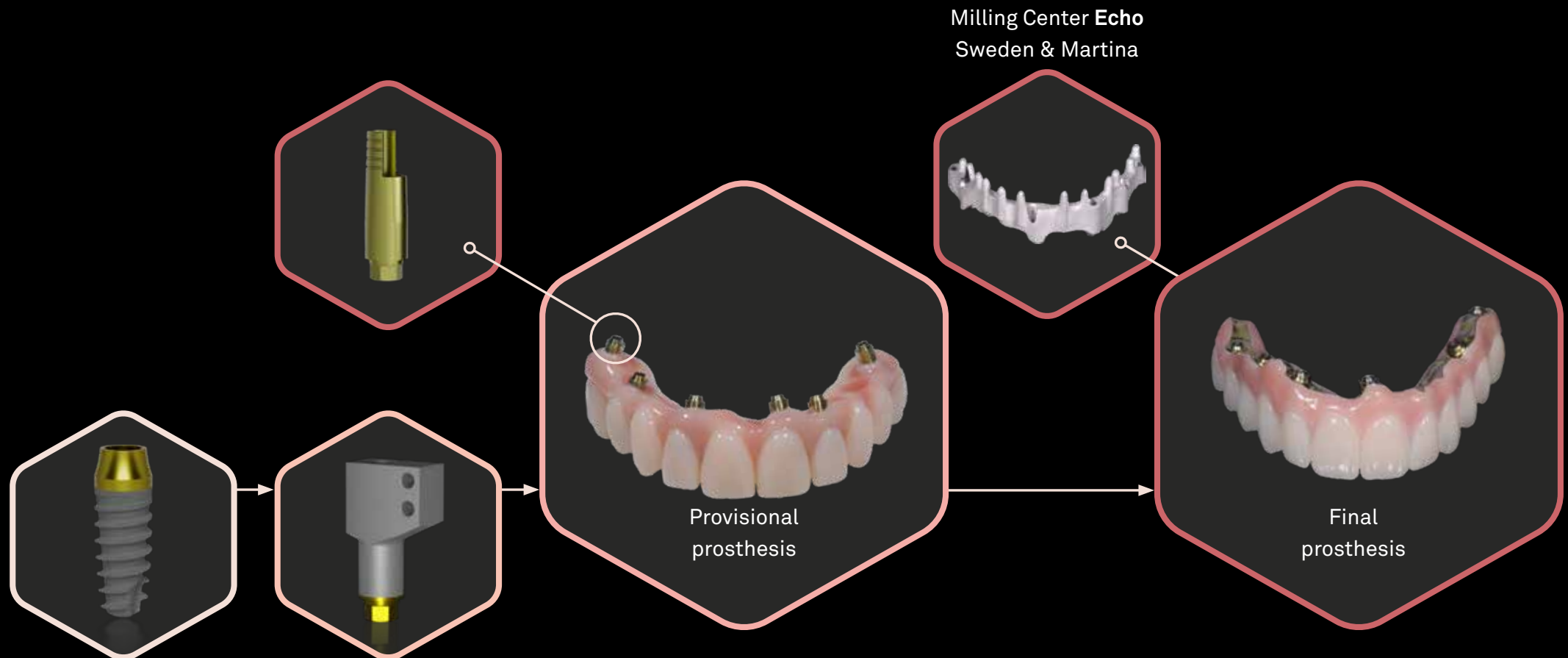
An example of a solution for a full arch with distally inclined Prama implants.

Courtesy of dr. Marco Csonka

Quick&Easy

Full arch procedure

Quick&Easy is a simple and fast technique to achieve a full arch rehabilitation without compromising on quality: it relies on a milled provisional fixed onto straight abutments (L-MDT) and on a final prosthesis built on a milled titanium bar, without intermediate elements thanks to the use of an angled screw. Thanks to the digital approach, the process is minimally invasive and predictable from the case design stage.

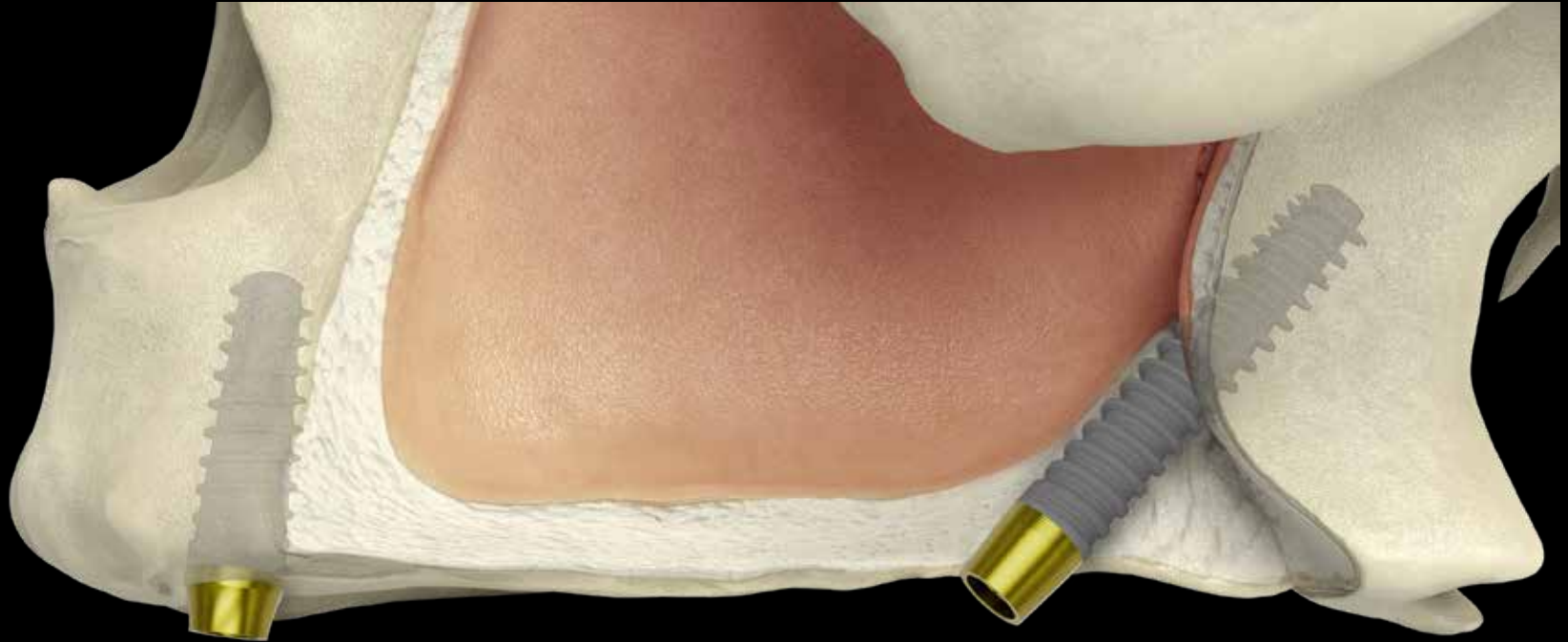

Courtesy of dr. Costantino Vignato and dt. Riccardo Finotello

Extreme solutions

Nasal and Pterygoid implants

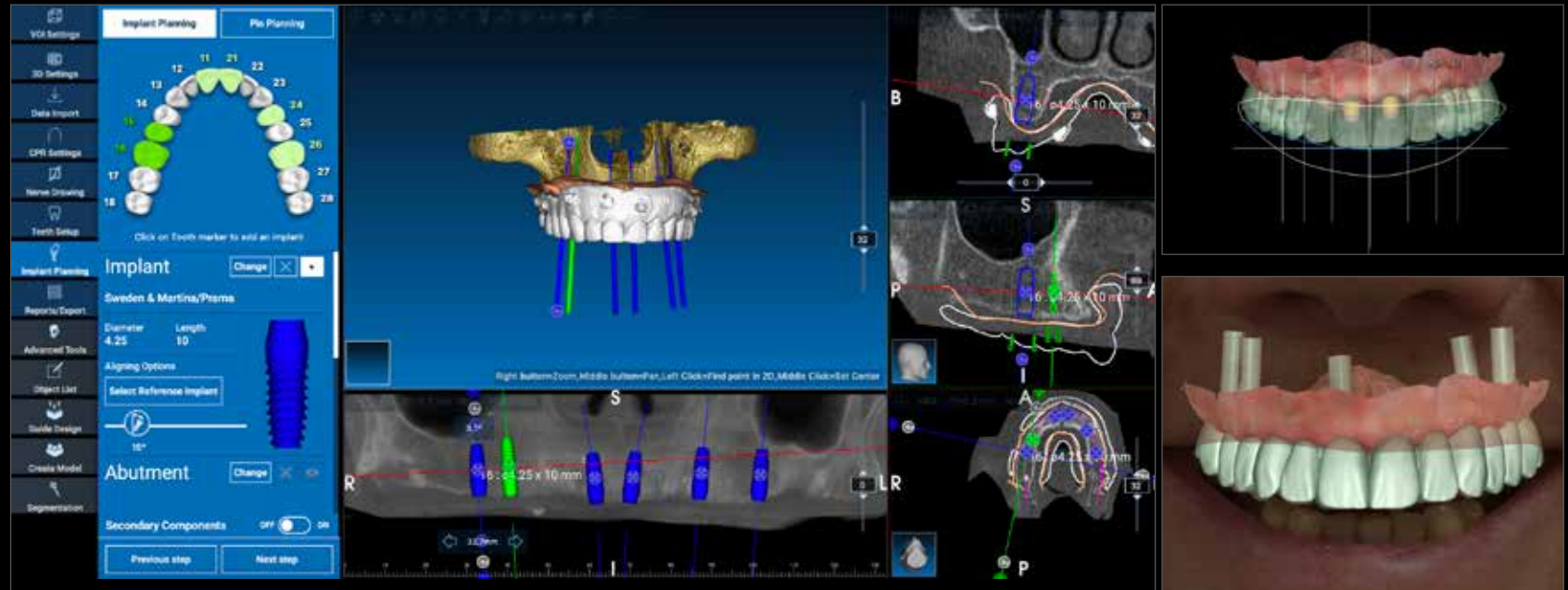
In the presence of severe atrophy, there are alternatives to bone regeneration that can increase the predictability of treatment and also allow immediate loading. The extension of the Prama range makes it possible to take advantage of the nasal and pterygoid positioning to increase the primary stability and biomechanical resistance of the entire rehabilitation. These techniques, within the reach of many medium-advanced implantologists, prove to be simple when combined with a serious pre-surgical study that allows to highlight the bone to be engaged, the inclination of the implant and the anatomical limitations.



The digital approach

Prima and guided surgery

The digital approach Prima and guided surgery Sweden & Martina is able to assist you from design to production of the surgical guide, model, and provisional prosthesis. The experience of Sweden & Martina and dedicated support will make the positioning of Prima even easier. The possibility of a flapless approach will result in a significantly shorter procedure and less pain and swelling during the patient's healing phase. To perform guided surgery with Prima implants, two complete and ergonomic kits have been designed, including all the necessary tools for a fully assisted surgery.




"When the placement of Prima implants is prosthetically guided during inserting and surgically guided during the implant insertion, it benefits the prosthetic emergence profiles and ensures appropriate shapes, optimal aesthetic results, and health of the peri-implant tissues."

Prof. Berta García Mira, Departament D'Estomatologia. Facultat De Medicina I Odontologia. Universitat De València




Watch the complete clinical case


The range




Prama Power Slim
short neck and
regular neck




Prama Power regular neck, short neck
and long neck



Prama Power RF regular neck,
short neck and long neck




Prama Power RF SL
regular neck and
long neck



Prama Power shorty
regular neck and long neck
cylindrical and tapered
morphology



Prama Power RF
shorty regular
neck



Prama Nasal short neck and
long neck, Prama Pterygoid
short neck and long neck



Discover the available
sizes for each
morphology

Bibliography

- a. Canullo L., Tallarico M., Pradies G., Marinotti F., Loi I., Cocchetto R.,
Soft and hard tissue response to an implant with a convergent collar in the esthetic area: preliminary report at 18 months,
Int J Esthet Dent 2017; 12:2-19:
- b. Canullo L, Menini M, Covani U, Pesce P,
Clinical outcomes of using a prosthetic protocol to rehabilitate tissue-level implants with a convergent collar in the esthetic zone: a 3-year prospective study,
J Prosthet Dent. 2019 Jun 18. pii: S0022-3913(19)30077-0. doi: 10.1016/j.prosdent.2018.12.022
- c. Valente N.A., Wu M., Toti P., Derchi G., Barone A,
Concave/convergent versus parallel/divergent implant transmucosal profiles impact on hard and soft peri-implant tissues: a systematic review with meta-analysis,
Int J Prosthodont . Sep/Oct 2020;33(5):553-564. doi: 10.11607/ijp.6726
- d. Cabanes Gumbau G, Pascual-Moscardò A, Penarrocha-Oltra D, Garcia-Mira B, Aizcorbe-Vicente J, Penarrocha-Diogo M,
Volumetric variation of peri-implant soft tissues in convergent collar implants and crowns using the biologically oriented preparation technique,
Med Oral Patol Oral Cir Bucal. 2019 Sep 1;24(5):e643-e651. doi: 10.4317/medoral.22946
- e. Agustín-Panadero R, Martínez-Martínez N, L. Fernandez-Estevan, J. Faus-Lopez, F. Sola-Ruiz,
Influence of transmucosal Area Morphology on Peri-implant bone loss in tissue-level implants,
The International Journal of Oral & Maxillofacial Implants, 2019; 34: 947-952. doi: 10.11607/jomi.7329
- f. Marchio V, Derchi G, Cinquini C, Miceli M, Gabriele M, Alfonsi F, Barone A,
Tissue level implants in healthy versus medically compromised patients: a cohort comparative study,
Minerva Stomatologica 2020 mese;69(0):000–000, Doi: 10.23736/S0026-4970.20.04359-9
- g. Prati C, Zamparini F, Canullo L, Pirani C, Botticelli D, Gandolfi MG,
Factors affecting soft and hard tissues around two-piece transmucosal implants: a 3 year prospective cohort study,
J Oral Maxillofac Implants 2020;35, doi: 10.11607/jomi.7778
- h. Agustín-Panadero, R.; Bermúdez-Mulet, I.; Fernández-Estevan, L.; Fernanda Solá-Ruiz, M.; Marco-Pitarch, R.; García-Selva, M.; Zubizarreta-Macho, Á.; León-Martínez, R.,
Peri-Implant Behavior of Tissue Level Dental Implants with a Convergent Neck.,
Int. J. Environ. Res. Public Health 2021, 18, 5232, Doi: 10.3390, ijerph18105232
- i. Palombo D., Rahmati M., Vignoletti F., Sanz-Esporrin J., Haugen H. J., Sanz M.,
Hard and soft tissue healing around implants with a modified implant neck configuration: An experimental in vivo preclipreclinical investigation,
Clin Oral Impl Res. 2021;00:1–15.
- j. Morón-Conejo B, Sanz-Sánchez I, Salido MP, Martínez-Rus F, Pradies G,
The effect of a convergent transmucosal neck on soft tissues and radiographic outcomes: a 1-year follow-up randomized controlled trial,
Clin Oral Investig 2023 Feb 7. doi: 10.1007/s00784-023-04892-9.
- k. Mandillo-Alonso V, Cascos Sanchez R, Antonaya-Martin JL, Laguna-Martos M,
Evaluation of peri-implant soft and hard tissues behavior in screw-retained crowns by the biologically oriented preparation technique: Ambispective longitudinal analytical study,
J Clin Exp Dent. 2022 Jan; 14(1): e64–e71, doi: 10.4317/jced.58924
- l. Mandillo-Alonso V, Cascos Sanchez R, Antonaya-Martin JL, Laguna-Martos M,
Soft tissue thickness evaluation in screw-retained crowns by the biologically oriented preparation technique,
J Clin Exp Dent 2021 Dec 1;13(12): e1209–e1215, doi: 10.4317/jced.58952

Discover the Prama world



Prama website



Dental Arena



Join our
S&M - COMMUNITY
WhatsApp group

**Sweden & Martina S.p.A.**

Via Veneto, 10
35020 Due Carrare (PD), Italy
Tel. +39.049.9124300
Fax +39.049.9124290
info@sweden-martina.com

www.sweden-martina.com
prama.sweden-martina.com

Sweden & Martina Ltd

Unit 1b
Amberley Court, Whitworth Road
Crawley, West Sussex, RH11 7XL
Toll free 0800 1123575
info.uk@sweden-martina.com

Sweden & Martina Inc.

Distributor for U.S.
4700 S Mill Ave, Ste B-16
PO Box 23748 - Tempe, AZ 85282
Toll free 1-844-8MARTINA (1-844-862-7846)
info.us@sweden-martina.com
www.sweden-martinainc.com

Sweden & Martina Mediterranea S.L.

España - info.es@sweden-martina.com
Sweden & Martina Lda
Portugal - info.pt@sweden-martina.com

The implants, standard prosthetic components and surgical instruments contained in this issue are Medical devices and are manufactured by Sweden & Martina S.p.A. They conform to the ISO 9001 and ISO 13485 standards and are certified with the CE in compliance with Regulation (EU) Medical Devices n. 2017/745.

The Sweden & Martina plant manufactures Medical Devices in compliance with the CGMPs in force in the USA and in other countries worldwide.



Some products may not be regulatory/released for sale in all markets.

All trademarks herein are the property of Sweden & Martina S.p.A. unless otherwise indicated.

This material is intended for laboratories and clinicians and is not intended for patient distribution.

This material is not to be redistributed, duplicated, or disclosed without the express written consent of Sweden & Martina S.p.A.

For additional product information, including indications, contraindications, warnings, precautions, and potential adverse effects, see Sweden & Martina S.p.A. website.

The contents are updated at the time of publication. Check with the company for any subsequent updates.



rev. 06-24
v01